wjpmr, 2023, 9(4), 139-141

SJIF Impact Factor: 5.922

WORLD JOURNAL OF PHARMACEUTICAL AND MEDICAL RESEARCH

www.wjpmr.com

Review Article

ISSN 2455-3301

WJPMR

FEMALE GONADAL DYSGENESIS; CAUSE OF PRIMARY AMENORRHEA: ABOUT A CASE AND REVIEW OF THE LITERATURE

Imane Laghrich*, Badiaa Ezziouani, Soukaina Laaraj, Moulay Abdellah Baba Habib, Jaouad Kouach

Gynecology-Obstetrics Department, Mohamed V. Military Training Hospital – Rabat.

***Corresponding Author: Imane Laghrich**

Gynecology-Obstetrics Department, Mohamed V. Military Training Hospital - Rabat.

Article Received on 20/02/2023 **Article Revised on 13/03/2023** **Article Accepted on 02/04/2023**

SUMMARY

Female gonadal dysgenesis is characterized by the absence or insufficient development of the ovaries. This is manifested by symptoms of hypogonadism, discovered during impuberism, which can vary according to the degree of development of the gonads. We report the case of a 15-year-old girl, with no particular history, who consulted for primary amenorrhea. Clinical examination revealed impuberism with an unambiguous female phenotype. The hormonal assessment showed a profile of hypergonadotropic hypogonadism. The genetic study revealed a normal karyotype at 46 XX. pelvic MRI showed utero-vaginal hypoplasia. However, the ovaries were not seen. Laparoscopy found a hypoplastic uterus with almost absent ovaries, reduced to fibrous bands and whose biopsy found fibrous tissue devoid of ovarian parenchyma, thus confirming the diagnosis of ovarian dysgenesis.

KEYWORDS: Pure gonadal dysgenesis, primary amenorrhea, impuberism, hypergonadotropic hypogonadism, premature ovarian failure, infertility.

INTRODUCTION

Female type gonadal dysgenesis is a primary ovarian anomaly that is defined by the absence or insufficient development of the ovary. It results in signs of hypogonadism discovered during impuberism with an unambiguous female phenotype.

It can be of variable degree depending on the stage of gonadal development.

PATIENT AND OBSERVATION

Patient information

This is a 15-year-old girl, with no particular history, who consulted for primary amenorrhea.

Clinical Results

On examination, the young girl presented a tall female morphotype (1.72 m for 62 kg) associated with impuberism, with virtually no axillary hair, little breast development and poorly developed pubic hair (score of Tanner: A1-S1-P2).

The patient was a virgin, hence the non-realization of the vaginal examination.

Diagnostic approach

The hormonal assessment objectified an ovarian failure with a collapsed estradiol (< 10 pg/ml) and an indosable AMH, high gonadotropins (FSH = 48 mIU/ml, LH = 12 mIU/ml). Androgens were normal.

The rest of the exploration of the hypogonadal axis came back normal.

The wrist X-ray revealed a delay in bone age (12 years).

The genetic study revealed a constitutional karyotype at 46 XX.

Ultrasound and pelvic MRI showed utero-vaginal hypoplasia and non-individualisable ovaries. In addition, absence of malformations in particular renal.

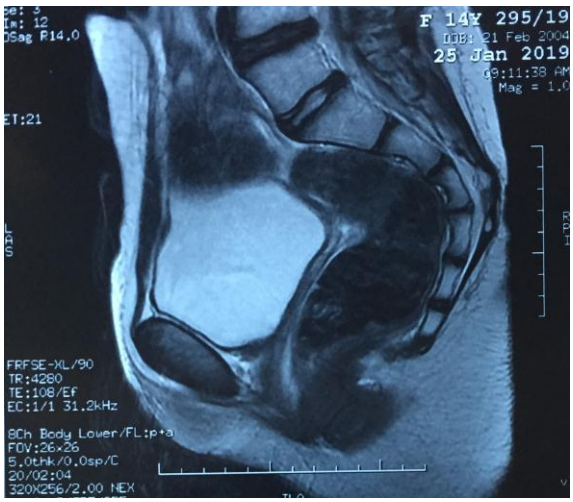

Figure 1: Pelvic MRI in sagittal section, showing uterovaginal hypoplasia.

Laparoscopy confirmed the diagnosis, finding a small hypoplastic uterus with almost absent ovaries, reduced to fibrous bands confirming the diagnosis of ovarian dysgenesis. A gonad biopsy was performed.

Histology confirmed the absence of ovarian parenchyma.

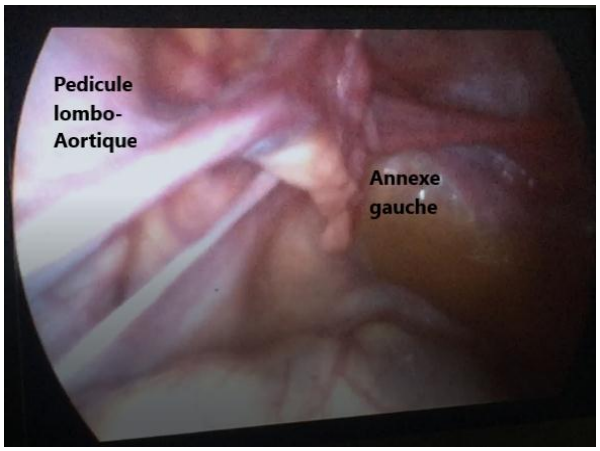

Figure2: Laparoscopic image of the left appendix showing the left ovary reduced to a fibrous band.

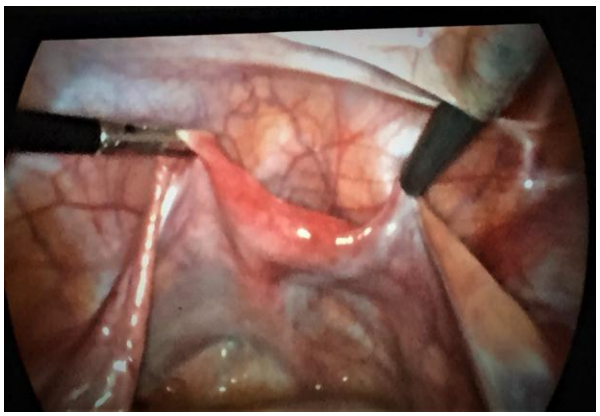

Figure3: Laparoscopic image showing a small uterus.

Therapeutic intervention and follow-up

The therapy was based mainly on psychological support for the patient and her family, as well as hormone replacement therapy based on estrogens to allow satisfactory mammary and uterine development.

DISCUSSION

Ovarian dysgenesis is due to genetic abnormalities in ovarian development. several hypotheses have been put forward involving a possible mutation of the anti-Müllerian hormone gene or even of the receptor for this hormone. Homozygous or compound heterozygous inactivating mutations in the follicle stimulating hormone receptor gene (FSHR; 2p21-p16), mutations in the BMP15 gene (Xp11.2) and mutations in the NR5A1 gene (9q33), among others.[1,2]

There are syndromic forms such as Perrault's syndrome (ovarian dysgenesis and deafness with or without cerebellar ataxia), pulmonary fibrosis-immunodeficiency-gonadal dysgenesis syndrome.[3] Rare cases of association with Rokitansky syndrome have been reported.[4,5,6]

The destruction of the gonad occurs at an early stage of embryogenesis, determining a female phenotype, regardless of the chromosomal sex. This explains the normal or high size due to delayed union of the growth plates, the absence of dysmorphism, marked impuberism, the presence of fibrous gonadal strips and the XX or XY chromosomal formula of these patients.[1,2,5]

In DGP XX, the hypothesis currently adopted to explain this accelerated apoptosis is that of the gene dosage effect. Both X chromosomes are active in oocytes throughout oogenesis. If one or more genes necessary for the vitality of the oocyte during meiosis are absent on one of the two chromosomes, accelerated atresia can occur by haplo insufficiency.[1]

XX pure gonadal dysgenesis is revealed in adolescence or early adulthood by the absence or delay of puberty, causing primary or sometimes secondary amenorrhea. Development of internal and external genitalia is normal.

The clinical examination must systematically look for weight loss, particular morphotype or malformation syndrome with or without mental retardation, neurological signs, or in favor of an endocrinopathy (adrenal, thyroid), galactorrhea.

The elevation of gonadotropins is the best diagnostic criterion, directing towards peripheral involvement.[6]

In our patient, the diagnosis was strongly suspected in view of the association with a picture of hypergonadotropic hypogonadism with a 46 XX chromosomal formula, a hypoplastic uterus and non-individualizable ovaries on ultrasound. Laparoscopy and biopsy confirmed the diagnosis.

Laparoscopy was not essential, but laparoscopy makes it possible to make an accurate assessment of abnormalities of the genital tract. Once done, it made it possible to verify the presence of a hypoplastic uterus and fallopian tubes, while the ovaries were reduced to simple fibrous strips.

Prophylactic gonadectomy is indicated in case of XY PGD, because of the high tumor risks.[7,8,9]

The substitution treatment in patients with DGP XX, was intended to obtain a development of secondary sexual characteristics, and to perpetuate psychologically reassuring rules

Management: The oral contraceptive pill is not indicated for the induction of puberty. Low-dose estrogen treatment should be continued for at least 2 years to allow satisfactory breast and uterine

development. The addition of a progestin is then recommended, allowing the onset of menstruation.

Monitoring must be regular to ensure that it is well followed and adapted to ensure normal feminization, uterine and vaginal trophicity allowing a satisfactory sex life. Associated with hygiene and dietary rules (vitaminocalcium intake, physical exercise, etc.), this treatment also aims to prevent osteoporosis by building up adult bone mass, as well as the cardiovascular risk linked to estrogen deficiency.

For the problem of infertility, oocyte donation remains to this day the only therapeutic recourse.[10,11,12]

CONCLUSION

Ovarian dysgenesis is caused by genetic abnormalities in the development of the ovaries. There may be associated syndromic forms.

Gonad destruction occurs early in embryogenesis, resulting in a female phenotype and absence of puberty.

The elevation of gonadotropins is the best diagnostic criterion. Laparoscopy helps confirm the diagnosis.

The treatment consists of hormonal treatment to develop secondary sexual characteristics and obtain regular periods. Calcium and vitamin D supplements may also be recommended.

Infertility can be a challenge for treatment, but pregnancy is possible through egg donation.

Conflicts of Interest

The authors declare no conflict of interest.

CONTRIBUTION OF THE AUTHORS

All authors contributed to the conduct of this work. The authors also declare that they have read and approved the final version of the manuscript.

REFERENCES

1. Marrakchi, A., Belhaj, L., Boussouf, H., Chraibi, A., & Kadiri, A. XX and XY pure gonadal dysgenesis: about 15 cases. Annals of Endocrinology, 2005; 66(6): 553–556.
2. Battin J. Gonadal dysgenesis of female phenotype. Encycl Med Chir (Scientific and Medical Editions Elsevier SAS, Paris, all rights reserved), Gynecology, 802-A24, 1998, Endocrinology-Nutrition, 2000; 10-027-C-30: 8.
3. Bellassoued M, Mnif M, Marouene H, Kammoun S, Ghorbel A, Mnif J, Sydrome de perrault: About two cases. Ann Endocrinol (Paris), 2001; 62(6): 534-537.
4. Aydos S, Tukun A, Bokesoy I. Gonadal dysgenesis and Mayer-Rokitansky –Kuster-Hauser syndrome in a girl with 46, X, del (X) (pter→ q22:) Archi Gynecol Obstet, 2003; 267: 173-174.
5. Gorgojo JJ, Almodovar F, Lopez E, Donnay S. Gonadal agenesis 46, XX associated with the atypical form of Rokitansky syndrome. Fertil Steril, 2002; 77(1): 185-187.
6. Kuttenn F, d'Acremont MF and Mowszowicz I. Abnormalities of sexual differentiation. Encycl Med Chir, EndocrinologieNutrition, 2003; 10-033-A-10: 26.
7. A. Marrakchi et al. Gonadal dysgenesis associated with Mayer-Rokitansky-Kuster-Hauser syndrome: a case report. Ann. Endocrinol. (Paris), 2004.
8. Lecomte P, Gervaise N. Fertility disorders of endocrine origin. Encycl Med Chir Endocrinology — Nutrition, 2001; 10-030-A-10: 25.
9. Boucekkine C, Vilain E, Mcelreavey K, Jaubert F, Brauner R, Thibaud E. Study of the sex determinism gene (SRY) in 46,XY gonadal dysgenesis. Ann Endocrinol (Paris), 1993; 54: 315-321.
10. Toublanc J E, Boucekkine C. Phenotypes related to SRY gene abnormalities. mt endocrinology, July-August, 2001; 3(4): 295-303.
11. Ronci-Chaix N, Christin-Maitre S. Premature ovarian failure. Encycl Med Chir Endocrinology-Nutrition, 10-027-C-20, 2003; 11.
12. www.orpha.net/consor/cgi-bin/OC_Exp.php?Lng=FR&Expert=243
13. H samira, K Hakkou, R Zermouni, A Chraibi, Pure gonadal dysgenesis 46XX; about a case, Annalesd'endocrinologies, 2013; 33-321.