wjpmr, 2023, 9(4), 04-05

SJIF Impact Factor: 5.922

WORLD JOURNAL OF PHARMACEUTICAL AND MEDICAL RESEARCH

www.wjpmr.com

Review Article

ISSN 2455-3301

WJPMR

RARE CASE OF SIMULTANEOUS RUPTURE OF BOTH PATELLAR TENDONS IN A 52-YEAR-OLD MAN: ABOUT A CASE AND REVIEW OF THE LITERATURE

M. Abakka*, H. El Ouagari, M. El Mhadder, M. J. Mekkaoui, M. Bouffetal, R. A. Bassir, M. Kharmaze, M. O. Lamrani and M. S. Berrada.

Department of Orthopeadics and Traumatology, CHU Ibn Sina de Rabat.

***Corresponding Author: Dr. M. Abakka**

Department of Orthopeadics and Traumatology, CHU Ibn Sina de Rabat.

Article Received on 23/01/2023 **Article Revised on 13/02/2023** **Article Accepted on 03/03/2023**

INTRODUCTION

The knee extensor device is essential to maintain the upright position. It is made up of the quadriceps and its tendon, the patella and the patellar tendon which attaches to the anterior tibial tuberosity. The four muscular heads of the quadriceps (vastus medialis, vastus intermedius, vastus lateralis, rectus femoris) join distally in their tendinous part and form the quadriceps tendon which is inserted on the superior pole of the patella. The patellar tendon attaches on the one hand to the lower pole of the patella and, on the other hand, to the anterior tibial tuberosity. These elements follow one another and form a single biomechanical unit allowing the active extension of the knee. Rupture of any of these elements results in complete inability to actively extension of the knee.

KEYWORDS: Patella-Tendon-Corticoïdes- Osgood Schlatter.

MATERIAL AND METHODS

We will report in this work a rare case of a 52-year-old patient, asthmatic under background treatment (salbutamol and corticosteroids), who presented a simultaneous rupture of the 2 patellar tendons following a sports accident treated by tendon suture and alignment of the patella in a single operation. The patient also had Osgood-Schlater disease.

RESULTS

The patient after a complete radiological assessment made of a standard X-ray of the 2 knees from the front and in profile which objectified a patella alta with a Caton Deschamps index > 1.2, supplemented by an osteoarticular ultrasound of the 2 knees which confirmed the rupture of the 2 patellar tendons. The patient was admitted to the operating room and benefited from a suture of the 2 patellar tendons, completed by a framing of the 2 patellae. The postoperative course was satisfactory, the 2 knees were immobilized with a Zimmer splint until the tendons had completely healed. Rehabilitation was started after 40 days.

DISCUSSION

The extensor apparatus is interrupted during a patellar tendon tear, and the patient is unable to actively extend the knee against gravity or maintain full knee extension. The kneecap, which is only subjected to the force of the quadriceps, migrates proximally and goes up. An interruption of the patellar tendon can easily be palpated since it is subcutaneous. On the standard X-rays, from the front and from the side, the patella is raised; the femoro-patellar procession is described as a "sunrise" with a disappearance of the joint line and the patella which is superimposed on the femoral condyles. Several radiological indexes exist and make it possible to objectify the extent of the ascent of the patella, and to compare its position with respect to the contralateral side. The most frequently used index is the Caton-Deschamps index. The advantage of this index is that it can be measured on any lateral knee x-ray, regardless of the degree of knee flexion. It is useful preoperatively for diagnosis, and postoperatively to assess the position of the patella and compare it to the contralateral side.

Early reconstruction (within a week of tearing) gives the best results. Various surgical techniques can be used. When the rupture occurs close to the patella, Krakow points in the patellar tendon passed transosseously into the patella provide good hold. The tension applied to the sutures must be well dosed in order to prevent a shortening of the patellar tendon and therefore a low patella (patella baja). The suture must be protected and completed by framing the patella.

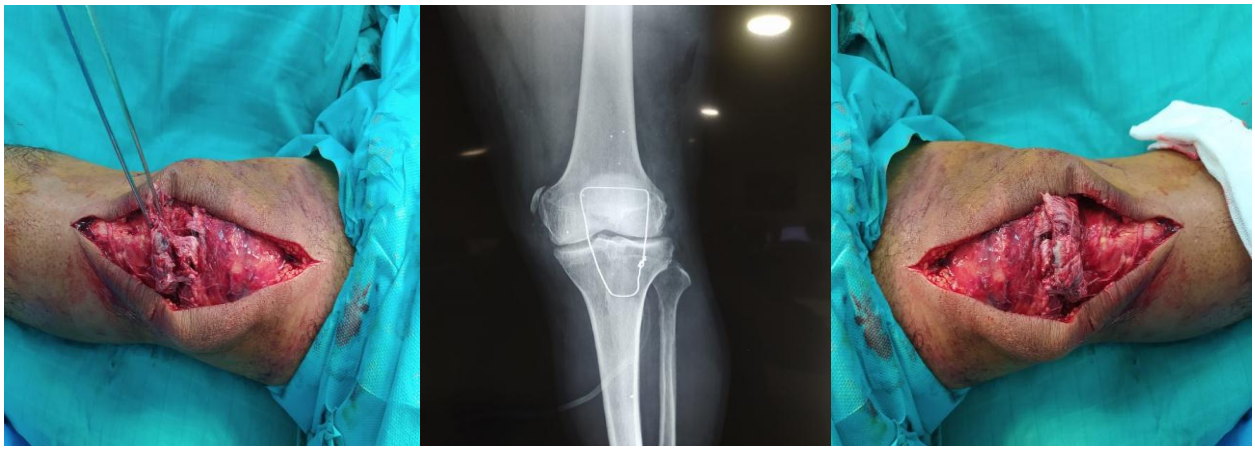

CONCLUSION

Ruptures of the extensor apparatus of the knee result in significant functional impotence of the lower limb. Tears of the quadriceps and patellar tendons and patellar fractures are rare and should be sought during the clinical examination. Early diagnosis allows rapid treatment in order to obtain optimal functional recovery.

REFERENCES

1. Archives of the Traumatology-Orthopedics Department of the CHU Ibn Sina in Rabat.
2. Iconography of the Traumatology-Orthopedics duty team of the Ibn Sina Hospital in Rabat.
3. Knee Extensor System Injuries - MSD Manuals.
4. Treatment of total ruptures of the patellar tendon: EM Consulte.
5. Ruptures of the extensor mechanism of the knee and patella fractures.