

**DEVELOPMENT OF A METHOD FOR PREOPERATIVE 3D PLANNING OF ORGAN-
SAVING AND MAPPING SURGERY FOR TUMORS OF THE PELVIC BONES**

Polatova D.Sh.*¹, Savkin A.V.¹, Davletov R.R.², Kahharov A.J.¹, Asamedinov N.K.¹, Nurjabov A.I.¹, Nasirov S.K.³, Abdusattorov O.K.¹

Tashkent State Dental Institute¹

Republican specialized scientific and practical medical center oncology and radiology²

Tashkent Medical Academy³

*Corresponding Author: Polatova D.Sh.

Tashkent State Dental Institute.

Article Received on 29/12/2022

Article Revised on 18/01/2023

Article Accepted on 08/02/2023

Due to the low prevalence, variety of histological forms of bone and soft tissue sarcomas (0.2-0.6% of all oncological diseases), their diagnosis and treatment present significant difficulties, are poorly understood and still remain the subject of research.^[1,2,3]

Tumor formations of the pelvic bones are characterized by a variety of histological forms, lesions, clinical course and prognosis. Bone tumors of the pelvis are presented as primary (benign and malignant) tumors, as well as tumors of metastatic origin.^[4,5,6,7,8,9,10,11,12]

Most studies have shown that of the malignant neoplasms in the pelvic bones, primary bone sarcomas are the most common, followed by soft tissue sarcomas and metastatic lesions. The analysis of available sources revealed inconsistency in data on the prevalence of various histological types of sarcomas of the pelvic bones.^[13,14,15]

According to studies, pelvic sarcomas account for 10-20% of bone sarcomas, and include such histological types as chondrosarcoma in adults, Ewing's sarcoma in children, and osteosarcoma in adolescents.^[16,17,18] According to M. _ U. _ Jawadetal., the most common of the primary sarcomas of the pelvic bones is chondrosarcoma, osteosarcoma is in second place^[19] While according to research G. Garsia et al. osteosarcoma, Ewing's sarcoma, and then chondrosarcoma were observed more frequently.^[20] The reason for the differences is that the number and age of patients varied within different limits, which was reflected in differences in prevalence rates. The most typical localization of the lesion in pelvic sarcomas is the ischial tuberosity, the iliac-pubic branch, the acetabulum.^[21,22,23,24]

Description of the preoperative planning technique using MSCT and 3D reconstruction

We used a preoperative planning method using MSCT (MSCT Revolution EVO. GE Healthcare 128 scan) and 3D reconstruction. The main objectives of preoperative planning were to determine the extent of the tumor and the involvement of surrounding organs and tissues in the process, as well as the precise determination of resection margins. A distinctive feature of the planning method we proposed was that in order to recreate the intraoperative situation during MSCT, the position of the patient during

the study fully corresponded to his position during the planned operation, which is really important due to the displacement of anatomical structures and changes in the topographic location of organs and bones pelvis. Significant moments at this stage were the use of various types of rollers, pillows, head restraints and fixing means, which thereby creating the intraoperative position of the patient. The advantage of using the MSCT machine for radiation therapy planning is the flat surface of the table, which corresponds to the surface of the operating table, while the standard MSCT machines have a concave surface.

In addition, the patient was marked with a permanent marker on the skin and metal wires and dotted metal marks, indicating important bone and anatomical landmarks, which in turn greatly facilitated orientation both during 3D planning and during surgery.

During the use of the Monaco planning system, the boundaries of the pelvic osteotomy were delineated, as well as measuring the distances from anatomically important points, as well as the angles and direction of the osteotomy path during the operation.

The criterion for the effectiveness of preoperative 3D planning was the status of resection margins after surgery, as well as the percentage of intraoperative

complications. In addition, MSCT of the resection volume in the preoperative period obtained during 3D reconstruction and MSCT after resection was compared .

The first stage of preoperative planning was the construction of a three-dimensional model of the pelvis using MSCT.

To carry out further stages of preoperative planning, a planning system for radiation therapy was used.

During preoperative 3D planning, it is possible to delineate the resection volume, as well as organs, tissues and neurovascular structures on CT sections. The scanning step was 1 mm. After MSCT is completed, the obtained images are transmitted via the local network to the planning system.

The contouring of the resection volume was carried out jointly with a radiation therapist and a surgeon-general oncologist. When planning the resection volume, both the macroscopic volume of the tumor, which is an instrumentally visualized volume of the tumor, and the boundaries of the possible microscopic spread of the tumor, which is 2 cm from the edges of the visible tumor, were taken into account.

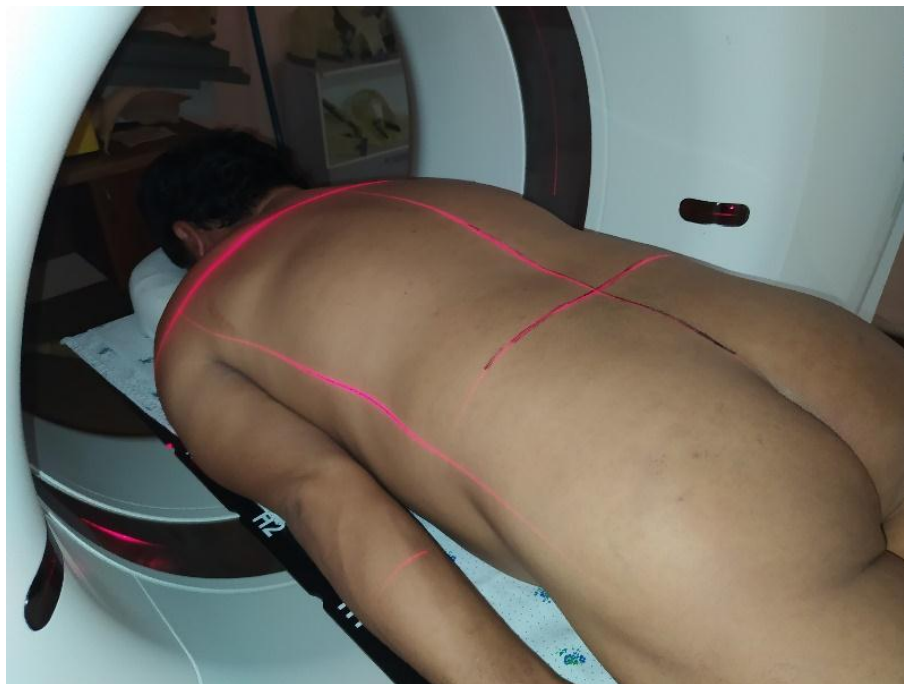The postoperative material was compared with the volume of resection planned before the operation using software.

Clinical example: 1

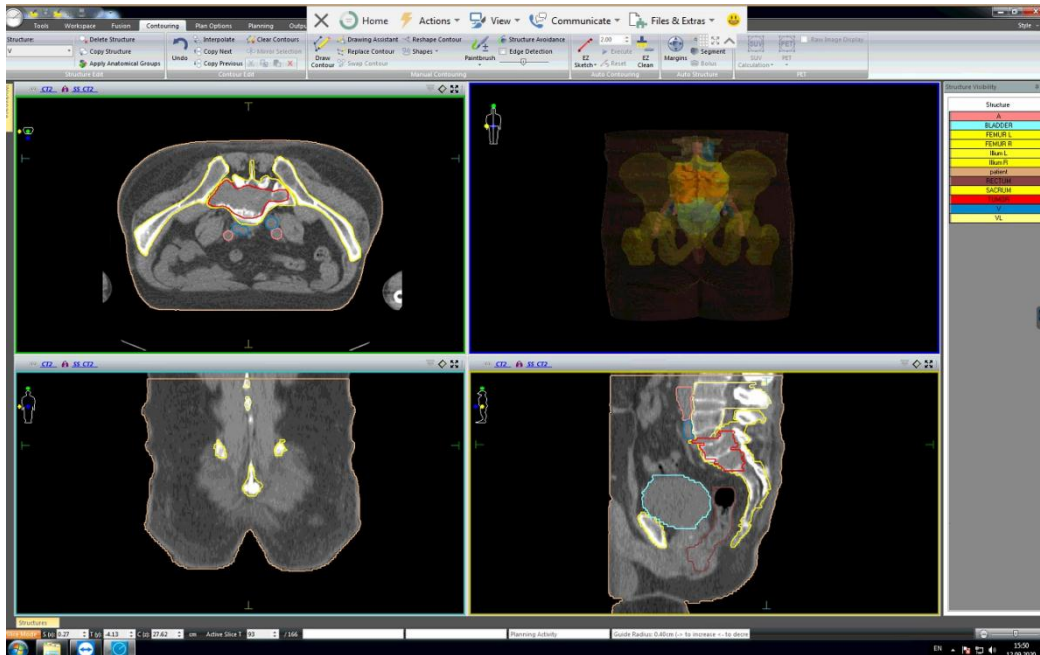
Patient B., born in 1976, was admitted to the hospital with complaints: pain in the sacrum with irradiation to the right leg.

From the anamnesis: *She considers herself ill around January 2019, when she noted pain in the lumbar spine radiating to the right leg. In September 2019, due to an increase in pain syndrome, MRI of the lumbosacral spine was performed, which revealed a volumetric formation of the S1 vertebra on the right. Biopsy performed. Histology - highly differentiated chondrosarcoma. Revision of histological preparations No. 4906/19 - Highly differentiated chondrosarcoma.*

Statuslocalis: *Gets around with crutches. Sparing lameness on the right. Visually in the right iliac region without signs of tumor growth. On palpation without clear signs of a tumor, local pain is noted. The skin is not changed. Movement in the hip joint in full. Peripheral lymph nodes are not enlarged. ECOG - 1. Karnofski - 90, VAS - 4. Watkins -1. Diagnosed with MN of the pelvis, sacrum and coccyx, diagnosis code according to ICD-10 C41.4. Chondrosarcoma sacral vertebrae S1 G2T2bN0M0 (IIB) The patient underwent preoperative planning according to our proposed method.*



Rice. 1 Preoperative laying and marking of the patient ;



Rice. 2 The process of delineating anatomical structures and tumors in various projections.

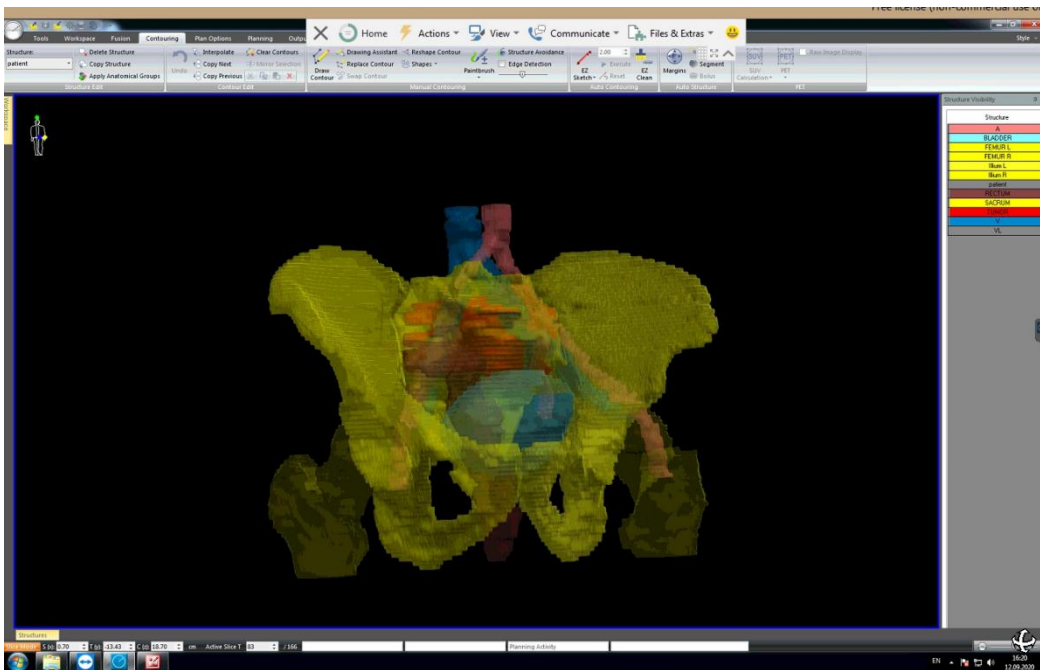
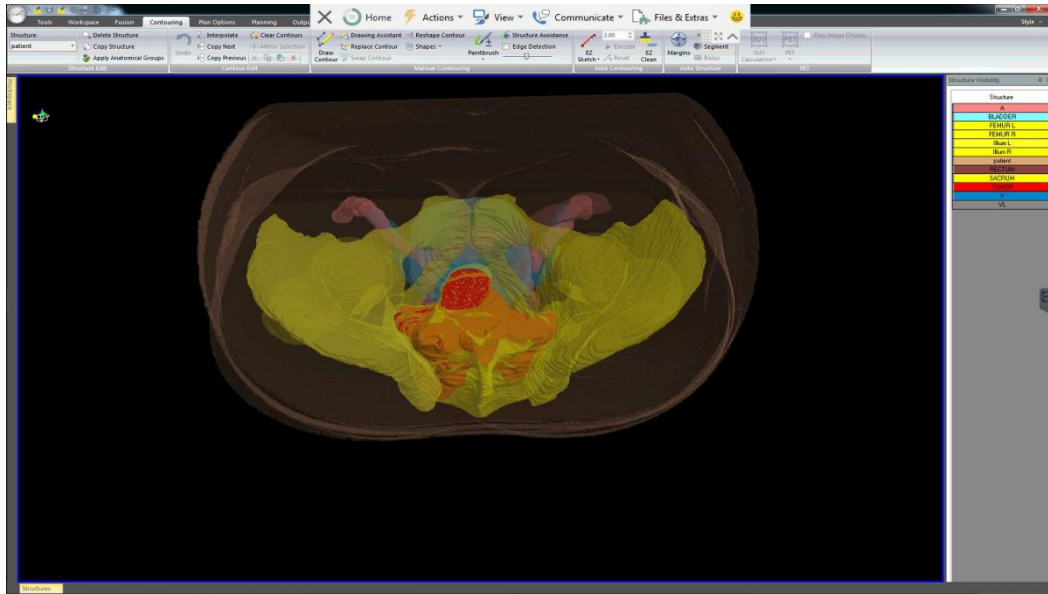
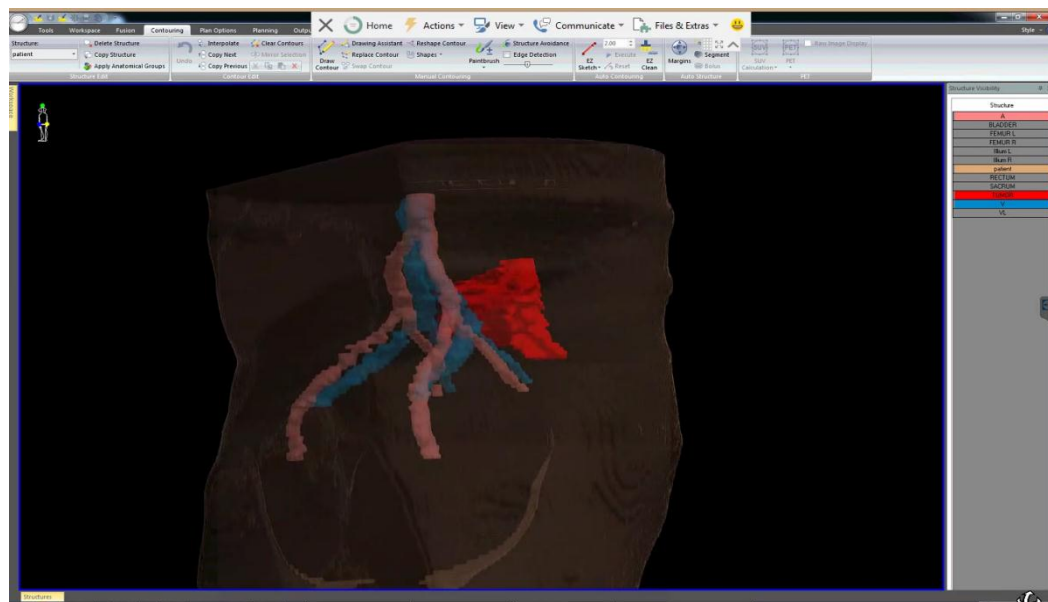


Fig.3 3D reconstruction of the pelvis with the allocation of blood vessels, rectum, bladder (front view)



Rice. 4 3 D reconstruction highlighting blood vessels, rectum, bladder (top view)



Rice. 5 Stage of determining the relationship of the tumor with large main vessels (side view)

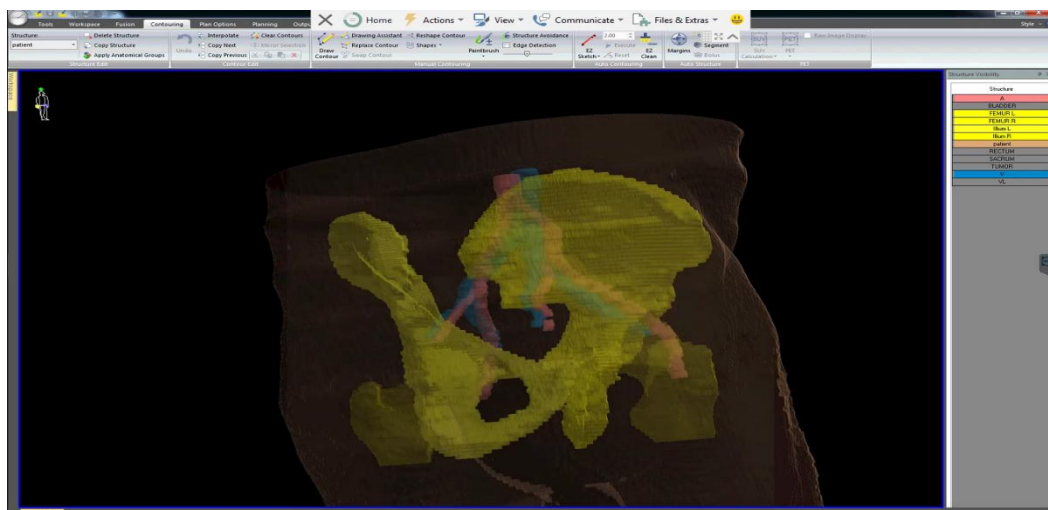


Fig.6 Stage 3 D reconstruction of the state after surgery (side view).

Surgical treatment was performed in the amount of sacrumectomy with restoration of the integrity of the pelvic ring.

The postoperative material, as well as MSCT after surgery, were compared with the MSCT picture of the macropreparation obtained by 3D planning.

Histological conclusion: the morphological picture corresponds to G2 chondrosarcoma of the sacrum.

Complications of surgical treatment: none.

For the current period of recurrence and metastases are not observed.

Clinical example: 2

Patient K., born in 1982, was admitted to the department of tumors of the musculoskeletal system with complaints of pain and the presence of a tumor in the left iliac region.

Anamnesis: She considers herself ill for about 2 years, when she noted the appearance of pain in the left iliac region. In August 2018, she noted an increase in pain, the appearance and growth of a tumor in the left gluteal region. Examination at the place of residence revealed a tumor of the left iliac bone. On December 6, 2018, an open biopsy of the tumor was performed, with a histological conclusion, suspicion of chondrosarcoma .

Description of the presented images (CT and MRI) - In the wing of the right iliac bone, a zone of lytic destruction is revealed, represented by a tumor of soft tissue radiological density, with extraosseous components , with a total size of 12x9x11.5 cm. . On the anterior surface of the iliac wing, the thickness of the extraosseous component is up to 3.2 cm, the iliac muscle is expansively pushed forward. On the posterior surface of the wing, the thickness of the extraosseous component is up to 8 cm; the gluteus maximus and medius muscles are pushed back. There is no connection between the tumor and the sciatic nerve (separated by muscle elements). The patient underwent a biopsy - the conclusion of osteosarcoma.

Status localis: The skin is not changed. Visually, a formation is determined in the right iliac region. On palpation, there is a dense consistency, moderately painful, 15x10 cm in size, without clear boundaries. Peripheral lymph nodes are not enlarged. There is no dysfunction of the pelvic organs. ECOG - 1. Karnofski - 80, VAS - 3. Watkins -1. Frenkel -E;

The diagnosis was established: Malignant neoplasm of the pelvis, sacrum and coccyx _ Osteosarcoma of the left ilium T 2 b N 0 M 0.

The patient underwent preoperative planning according to our proposed method.

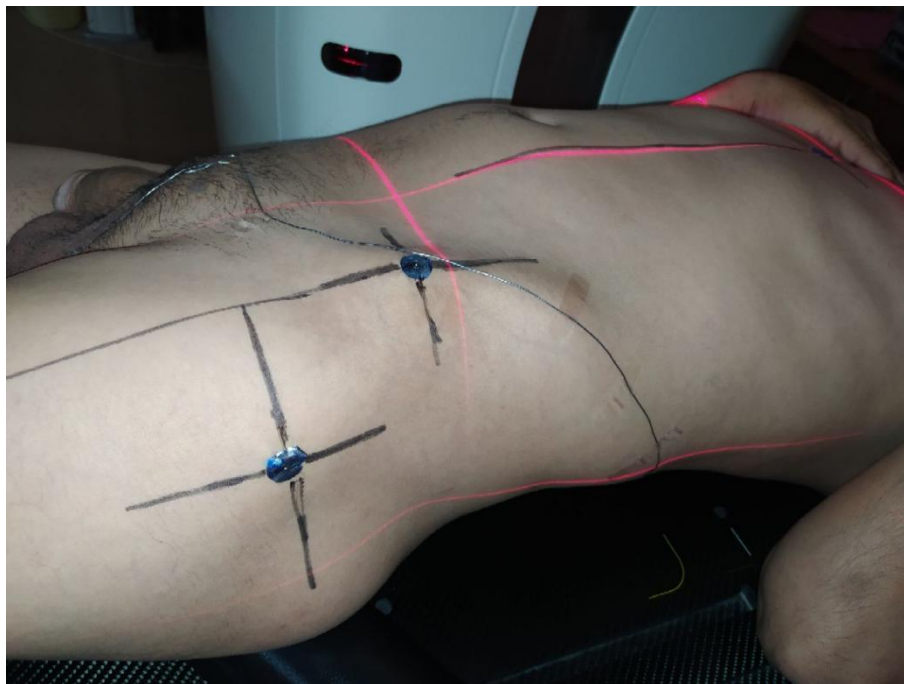


Fig.7 Preoperative laying and marking of the patient ;

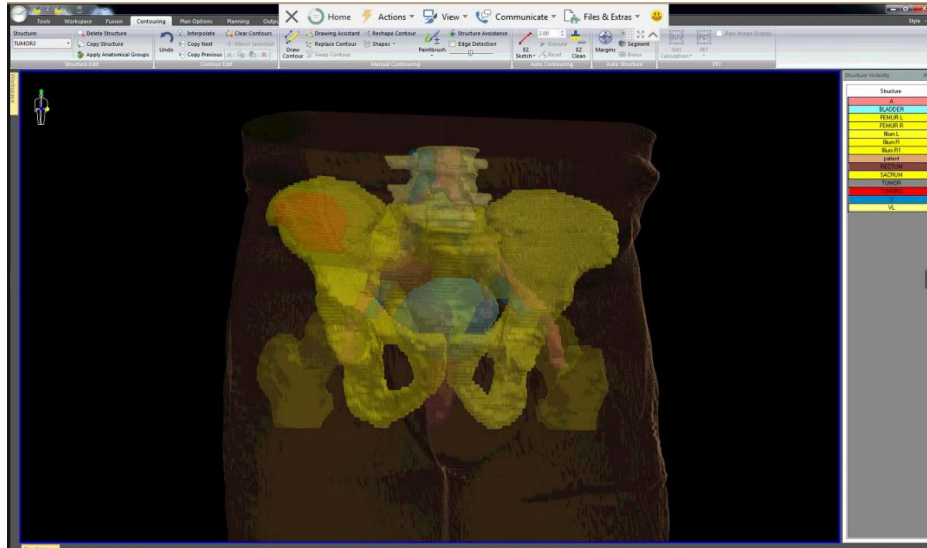
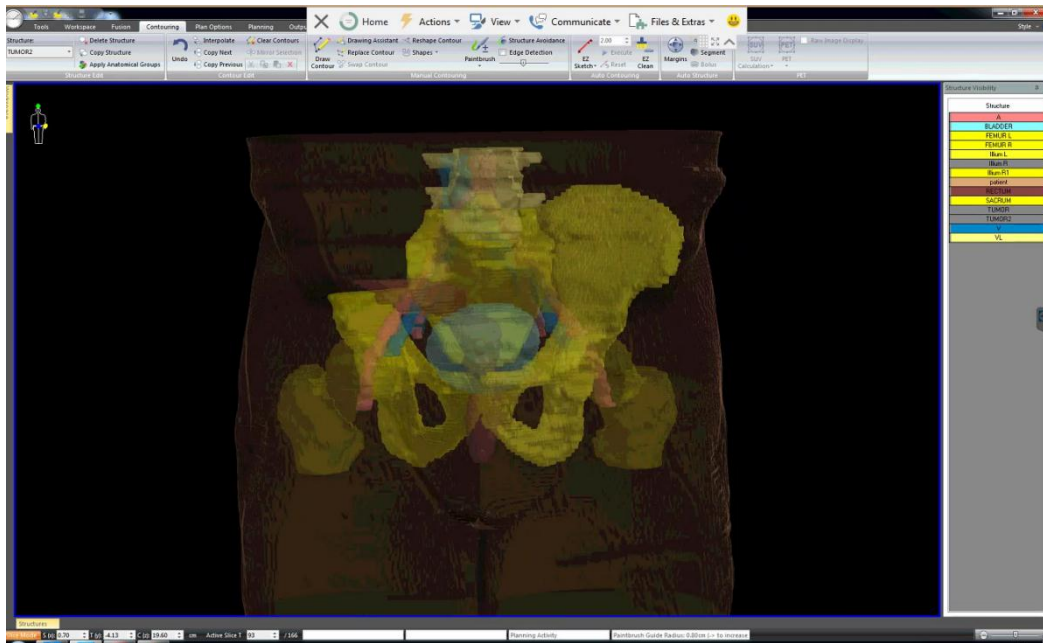


Fig.8 3D reconstruction of the pelvis with the allocation of blood vessels, rectum, bladder (front view)



Rice. 9 Stage 3 D reconstruction of the condition after surgery (front view)

An operation was performed resection of the ilium in the amount of PI. The postoperative material, as well as MSCT after surgery, were compared with the MSCT picture of the macropreparation obtained by 3D planning.

Histological conclusion: No. 18284/2019 The pathohistological picture is most consistent with chondroblastic osteosarcoma of a high degree of malignancy (high grade). The tumor grows into the subcutaneous fat of the skin flap. The edges of the resection of the preparation (bone and soft tissue structures), without signs of neoplastic growth. Complications of surgical treatment: none. For the current period of recurrence and metastases are not observed.

Clinical example: 3

Patient V., born in 1978, IB No, was admitted to the hospital with complaints: pain in the left lower limb, lameness

From the anamnesis: He considers himself ill around March 2019, when he noted pain in the left lower limb. In June 2019, due to increased pain syndrome, MSCT of the pelvic bones was performed, which revealed a mass formation in the acetabular region on the left. Biopsy performed. Histology - low-grade chondrosarcoma.

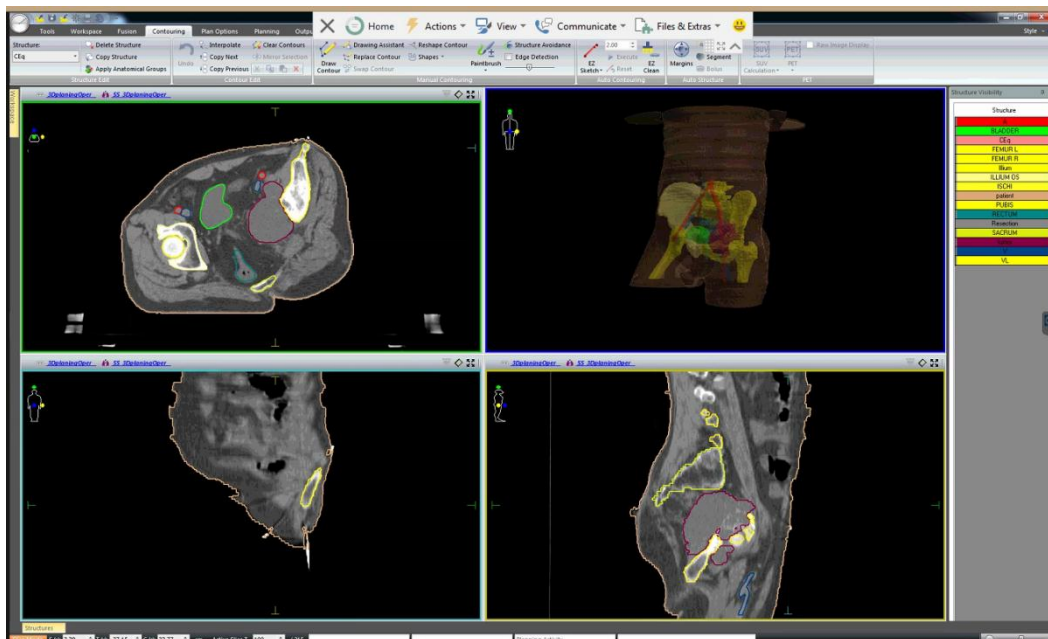
Status localis: Gets around with crutches. Sparing lameness on the left. Visually in the left iliac region without signs of tumor growth. On palpation without clear signs of a tumor, local pain is noted. The skin is not changed. Movement in the hip joint is limited. Peripheral lymph nodes are not enlarged. ECOG - 1. Karnofski - 90, VAS - 4. Watkins - 1.

Diagnosed with MN of the pelvis, sacrum and coccyx, diagnosis code according to ICD-10 C41.4. Chondrosarcoma left ilium in the region of the

acetabulum T2N0M0
The patient underwent preoperative planning according to our proposed method.

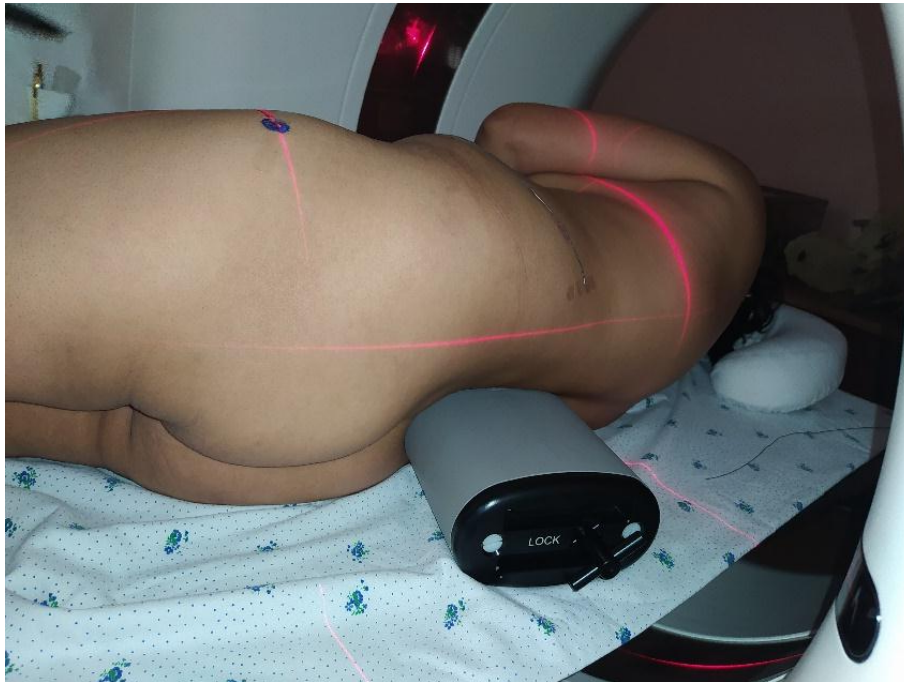

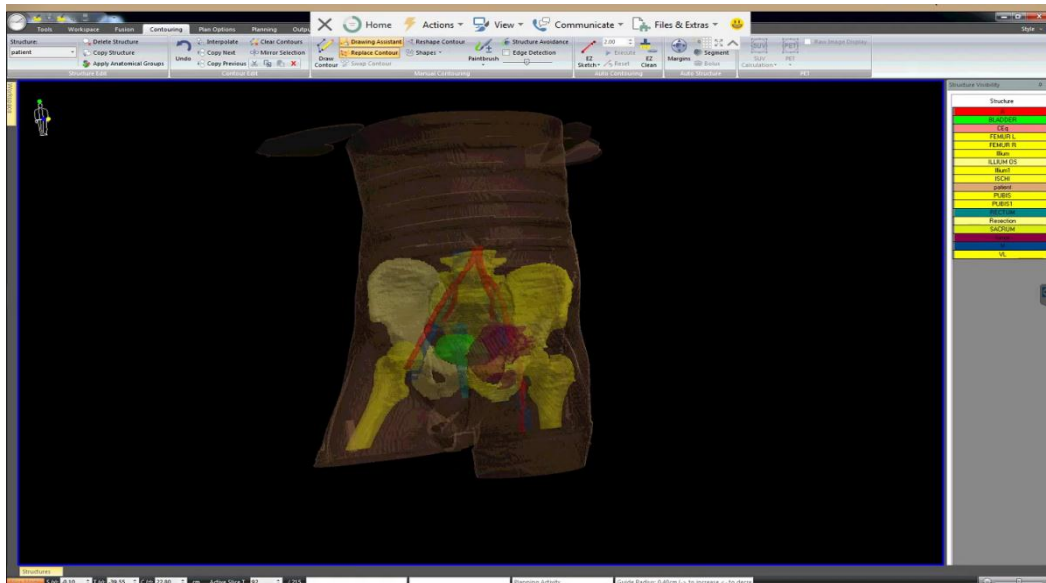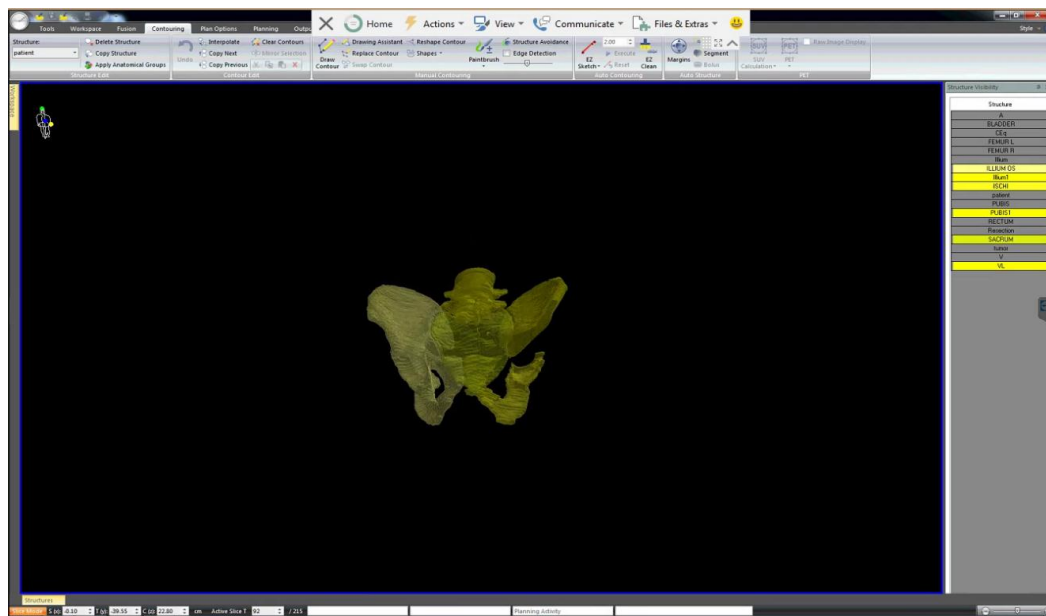
Fig. 10 Preoperative laying and marking of the patient



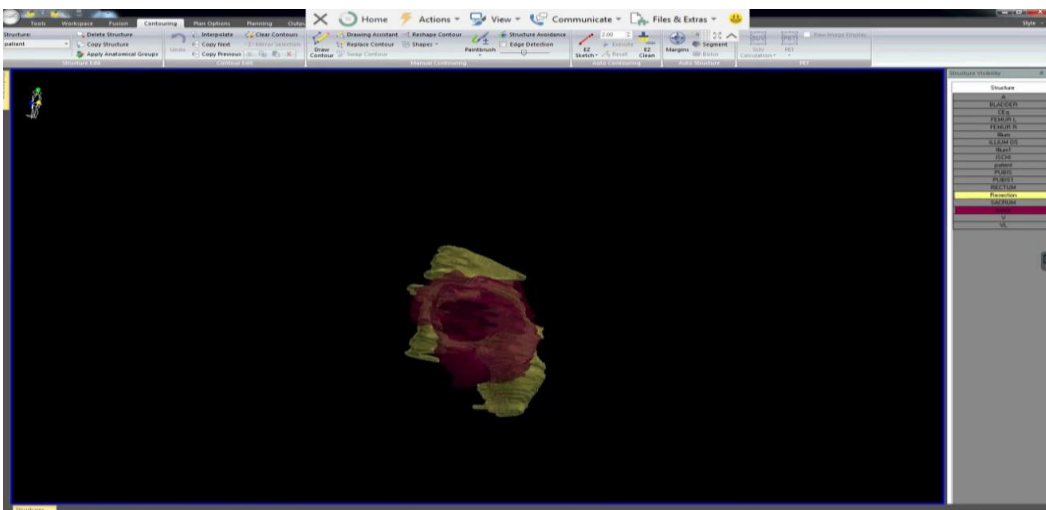
Rice. 11 3D reconstruction of the pelvis with exposure of blood vessels, rectum, bladder (front view)



Rice. 12 3D reconstruction of the pelvis with exposure of vessels, rectum, bladder (front view)



Rice. 13 Stage 3 D reconstruction of the condition after surgery (front view)



Rice. 14 Stage 3 D of macroscopic reconstruction (side view)

An operation was performed resection of the ilium in the amount of PI.

The postoperative material, as well as MSCT after surgery, were compared with the MSCT picture of the macropreparation obtained by 3D planning.

Histological conclusion: classic low-grade (grade 3) chondrosarcoma.

Complications of surgical treatment: none.

For the current period of recurrence and metastases are not observed.

In order to study the effectiveness of preoperative planning, we studied the time of surgical interventions, the number of repeated intraoperative resections, and the status of resection margins.

Table 1

Comparative analysis of the duration of surgery for tumors of the pelvic bones with/without the use of preoperative 3D planning.

| Duration of resection of the pelvic bones | Average duration (min) |
|---|-------------------------|
| using 3D planning methodology | 60.95±7.3 |
| without using the 3D planning technique | 81.9±10.54 |

$t=3.705$, $p < 0.05$, degree of freedom =9

Table 2

Resection Margin Status and Percentage of Intraoperative Resections Depending on the Use of Preoperative 3D Planning.

| Parameter | Using 3D planning | | Without using 3D planning | | χ^2 | p |
|------------------------------------|-------------------|-----|---------------------------|------|----------|-------|
| Status of resection margins | | | | | | |
| Positive resection margins | 0 | 0 | eight | 30.8 | 7.134* | 0.008 |
| Negative resection margins | 21 | 100 | fourteen | 53.8 | 7.134* | 0.008 |
| Intraoperative resections | | | | | | |
| There is | 0 | 0 | 6 | 23.1 | 4.578* | 0.033 |
| Not | 21 | 100 | 16 | 61.5 | 4.578* | 0.033 |
| intraoperative bleeding | | | | | | |
| There is | 0 | 0 | 3 | 13.6 | 1.336* | 0.248 |
| Not | 21 | 100 | 19 | 86.4 | 1.336* | 0.248 |

*value of χ^2 criterion with Yates correction (number of observations in one group >5)

When analyzing the results of using the preoperative planning proposed by us, a statistically significant reduction in the duration of the operation was revealed, due to a decrease in decision-making time, as well as a more accurate idea of the topographic location of the tumor, as well as its relationship with the surrounding anatomical structures. In addition, it should be noted that in the group of patients who underwent preoperative 3D planning, there was no resection, as well as a negative status of the resection margins in histopathological examination. Also, in this group, there was no intraoperative complication in the form of bleeding.

CONCLUSION

Resections of the pelvic bones, especially in the area of the ischial tuberosity and the iliac sacral joint, are technically complex surgical interventions due to the complex geometric three-dimensional structure of the pelvic bones, as well as the proximity of important organs and neurovascular structures. The high percentage of local recurrences is due to the complexity of the anatomical and topographic structure of the pelvis and the limited operational working field, and according to various authors, it is 28-35%. In addition, incorrect planning, without taking into account the soft tissues of

the pelvic region, or its failure to perform, leads to incorrect performance of intraoperative osteotomy, which, in turn, can have far-reaching consequences, expressed in a decrease in local control.

Preoperative planning using modern methods of radiation imaging makes it possible to determine with high accuracy the surgical tactics for pelvic tumors, which is due to the possibility of determining the important anatomical structures adjacent to the tumor (vascular-nervous structures, hollow organs), planning the resection volume, as well as studying the macropreparation. It also provides an opportunity to compare the pre- and postoperative state after the operation, as well as the volume of the resected bone fragment with the planned one. All these data play an important role in determining further treatment tactics, as well as an individual approach to adjuvant chemotherapy and radiotherapy.

REFERENCES

1. Blay JY, Soibinet P, Penel N et al. Improved survival using specialized multidisciplinary board in sarcoma patients. *Ann Oncol.*, 2017; 28: 2852–2859.
2. Brewster DH, Clark D, Hopkins L et al. Subsequent hospitalization experience of 5-year survivors of

- childhood, adolescent, and young adult cancer in Scotland: a population based, retrospective cohort study. *BrJ Cancer*, 2014; 110: 1342–1350.
3. Frezza AM, Cesari M, Baumhoer D et al. Mesenchymal chondrosarcoma: prognostic factors and outcome in 113 patients. A European Musculoskeletal Oncology Society study. *Eur J Cancer*, 2015; 51: 374–381.
 4. Namozova F.Sh. Evaluation of limb function after performing mutilation operations in patients with bone sarcomas//Clinical and experimental oncology.-2018.-№3.-P.183
 5. Angelini A, Guerra G, Mavrogenis AF, Pala E, Picci P, Ruggieri P Clinical outcome of central conventional chondrosarcoma. *JSurg Oncol.*, 2012; 106(8): 929–937.
 6. Behjati S, Tarpey PS, Presneau N et al. Distinct H3F3A and H3F3B driver mutations define chondroblastoma and giant cell tumor of bone. *Nat Genet*, 2013; 45: 1479–1482.
 7. Bickerstaffe AC, Darby SC. Cancer risk in 680,000 people exposed to computed tomography scans in childhood or adolescence: data linkage study of 11 million Australians. *BMJ* 2013 May 21; 346: f2360.
 8. Bischoff M, Bischoff G, Buck A, von Baer A, Pauls S, Scheffold F, Schultheiss M, Gebhard F, Reske SN. Integrated FDG-PET-CT: its role in the assessment of bone and soft tissue tumors. *Arch Orthop Trauma Surg.*, 2010 Jul; 130(7): 819e27.
 9. Bramer JA, van Linge JH, Grimer RJ, Scholten RJ. Prognostic factors in localized extremity osteosarcoma: a systematic review. *Eur J Surg Oncol.*, 2009; 35: 1030–1036.
 10. Fiorenza F, Abudu A, Grimer RJ, Carter SR, Tillman RM, Ayoub K, et al. Risk factors for survival and local control in chondrosarcoma of bone. *J Bone Joint Surg Br*, 2002; 84(1): 93–9.
 11. Fletcher CDM, Bridge JA, Hogendoorn PCW, Mertens F. Pathology and genetics of tumors of soft tissue and bone. World Health Organization. Lyon: IARC Press 2013.
 12. Gaspar N, Hawkins DS, Dirksen U et al. Ewing sarcoma: current management and future approaches through collaboration. *J Clin Oncol.*, 2015; 33: 3036–3046.
 13. Gru'newald TG, Bernard V, Gilardi-Hebenstreit P et al. Chimeric EWSR1–FLI1 regulates the Ewing sarcoma susceptibility gene EGR2 via a GGAA microsatellite. *Nat Genet*, 2015; 47: 1073–1078.
 14. Li G, Wang L, Pan W, Yang F, Jiang W, Wu X, Kong X, Dai K, Hao Y In vitro and in vivo study of additive manufactured porous Ti6Al4V scaffolds for repairing bone defects. *Sci Rep.*, 2016; 6: 34072.
 15. Li H, Qu X, Mao Y, Dai K, Zhu Z. Custom acetabular cages offer stable fixation and improved hip scores for revision THA with severe bone defects. *Clinic Orthop Relat Res.*, 2016; 474(3): 731–740.
 16. Pakos EE, Grimer RJ, Peake D et al. The 'other' bone sarcomas: prognostic factors and outcomes of spindle cell sarcomas of bone. *J Bone Joint Surg Br*, 2011; 93: 1271–1278.
 17. Wong KC, Kumta SM, Geel NV, Demol J One-step reconstruction with a 3D-printed, biomechanically evaluated custom implant after complex pelvic tumor resection. *Comput Aided Surg.*, 2015; 20: 14–23.
 18. Jawad MU, Haleem AA, Scully SP. Malignant sarcoma of the pelvic bones: treatment outcomes and prognostic factors vary by histopathology. *cancer.*, 2011 Apr 1; 117(7): 1529–41.
 19. Garcia, Jairo Greco, Martinez, Adriano, Garcia Filho, Reynaldo Jesus, Petrilli, Marcelo Toledo, & Viola, Dan Carai. Epidemiological characteristics of patients with pelvic tumors submitted to surgical treatment. *Revista Brasileira de Ortopedia*, 2018; 53(1): 33–37.
 20. Friedrich MJ, Schmolders J, Michel RD, Randau TM, Wimmer MD, Kohlhof H, Wirtz DC, Gravius S Management of severe periacetabular bone loss combined with pelvic discontinuity in revision hip arthroplasty. *Int Orthop.*, 2014; 38(12): 2455–2461.
 21. Li H, Qu X, Mao Y, Dai K, Zhu Z Custom acetabular cages offer stable fixation and improved hip scores for revision THA with severe bone defects. *Clinic Orthop Relat Res.*, 2016; 474(3): 731–740.
 22. Li J, Wang Z, Guo Z, Chen GJ, Yang M, Pei GX: Irregular osteotomy in limb salvage for juxta-articular osteosarcoma under Joel L. Mayerson, MD, et al April 2014; 22(4): 221.
 23. Sabourin M, Biau D, Babinet A et al Surgical management of pelvic primary bone tumors involving the sacroiliac joint. *Orthop Traumatol Surg Res.*, 2009; 95: 284–292.