

**CONTRIBUTION OF STANDARD RADIOGRAPHY IN THE MANAGEMENT OF POST-TRAUMATIC HEMOTHORAX IN THE THORACIC SURGERY DEPARTMENT OF THE DONKA NATIONAL HOSPITAL****SAKHO Aminata<sup>1\*</sup>, BALDE Thierno Hamidou<sup>2</sup>, DOUMBOUYA Ibrahima Sory<sup>3</sup>, DIALLO Souleymane Mbara<sup>4</sup>, DRAME Karamba<sup>5</sup>, BARRY Habourayatu<sup>6</sup>**<sup>\*1</sup>Médecin Radiologue Service de Radiologie CHU Donka Conakry Guinée.<sup>2</sup>Médecin Radiologue Service de Radiologie Hôpital National Ignace DEEN Conakry Guinée.<sup>3</sup>Médecin Radiologue Service d'Imagerie Caisse Nationale Sécurité Sociale Conakry Guinée.<sup>4,5,6</sup>Médecin DES Neurologie Service de neurologie, CHU Conakry Guinée.**\*Corresponding Author: SAKHO Aminata**

Médecin Radiologue Service de Radiologie CHU Donka Conakry Guinée.

Article Received on 29/12/2022

Article Revised on 18/01/2023

Article Accepted on 08/02/2023

**SUMMARY**

**Introduction:** post-traumatic hemothorax is an urgent and medico-surgical condition whose frequency is constantly increasing. Standard chest radiography in the trauma patient remains prominent in the initial evaluation of chest injuries. The aim of this work was to study the clinical, paraclinical and therapeutic epidemiological profile of this pathology. **Materials and Methods:** This is a 10-month prospective descriptive study of 30 cases of patients admitted for post-traumatic hemothorax in the thoracic surgery department of the Donka National Hospital in the Republic of Guinea from April 1, 2020 to 31 January 2021. **Results:** The mean age was 33.60 years and a sex ratio of 4. Road accidents were the main etiologies of hemothorax. Hemothorax was low abundance in 17 patients (56.67%), medium abundance in 7 patients (23.33%) and high abundance in 6 patients (20%). Ninety-seven percent (97%) of our patients had immediate clinical and radiological improvement after pleural drainage. Among these patients, only one presented a complication type of infection. We recorded one case of death (3%). **Conclusion:** hemothoraxes constitute a medico-surgical emergency which is highly life-threatening. We were able to observe that the patients admitted to the thoracic surgery department of the CHU Donka in whom the diagnosis of post-traumatic hemothorax is established are relatively young subjects and mostly male.

**KEYWORDS:** Posttraumatic hemothorax, Pleural drainage, Thoracic surgery, standard radiography.**INTRODUCTION**

Posttraumatic hemothorax is a medical-surgical emergency defined by the presence of fresh, pure blood in the pleural cavity. It occurs mainly as a result of chest trauma and is observed in 40-60% of chest trauma even in the absence of visible rib fracture on the rib.<sup>[1]</sup> Standard chest radiography in traumatized patients remains at the forefront of initial assessment of chest lesions. It must be carried out as soon as the admission and allows to answer only one essential question : should we urgently perform a thoracic drainage? Hemothorax is visible on standard standing images from 200 ml volumes and remains difficult to see if the shot is taken supine for such volumes.<sup>[2]</sup> Each of the lesions of the different parietal, pleural, pulmonary or mediastinal compartments can be the cause of respiratory distress but their association makes it all the severity. The prognosis of his patients will therefore depend on the severity of the chest lesions, the time taken to manage them and the first therapeutic actions performed.<sup>[3]</sup> Hemothorax has seen its frequency increase in parallel with that of trauma

of the thorax, because of the increase of the accidents of the public way, the increase of the various assaults by knife and firearm, during the various crises policies the country has experienced.<sup>[4-5]</sup> The etiologies of hemothorax are diverse. Of the etiological circumstances encountered, road accidents are the most frequent with 43.24% in 2014 in Guinea.<sup>[1-6]</sup> In the United States, an approximate estimate of the occurrence of trauma-related hemothorax approaches 300,000 cases per year.<sup>[7]</sup> In Africa, in Burkina Faso in 2008 a study conducted by Diallo C<sup>[8]</sup> shows that traumatic hemothorax accounts for 31.53% of chest injuries in the general surgery and digestive department while in Guinea in 2008, Barry FM, had found a frequency 3,33% of hemothorax in the thoracic surgery department of the Donka National Hospital in a study on closed chest trauma.<sup>[4]</sup> The diagnosis of posttraumatic hemothorax is based on a bundle of clinical arguments (chest pain, dyspnea, cough, tachycardia, chest bleeding wound, headache, etc.) and para-clinical (imaging and biology), the prognosis depends on the nature of the lesions and especially on the

early diagnosis and its management. Only rapid and complete drainage allows healing without sequelae in 90% of cases.<sup>[9]</sup>

The objective of our study was to study the clinical, para-clinical and therapeutic epidemiological profile of post-traumatic hemothorax in the thoracic surgery department of the Donka National Hospital.

**MATERIALS AND METHODS:** This was a 10-month prospective descriptive type study from April 1, 2020 to January 31, 2021 that covered all patients who had stayed at the Donka National Hospital Thoracic Surgery Department for a post-hemothoraxtraumatic. Included in this study were patients received, treated and followed at the Donka National Hospital Thoracic Surgery for Posttraumatic Hemothorax during the period. Thus 30 patients were retained. The following epidemiological variables have been studied: frequency, sex, age of patients divided into 6 groups (3-12 years, 13-22 years; 23-32 years; 33-42 years; 43-52 years and 53 years) Face radiography, Profile and the costal grill were looking for an intrapleural fluid effusion with appreciation of its abundance (opaque hemithorax if profuse effusion; dense and homogeneous opacity of the base if of medium abundance; simple filling of the costo-diaphragmatic cul-de-sac if minimal effusion), fractures (costales) and diaphragmatic lesions. The hematic nature of the effusion was objectified by the pleural puncture. The medical treatment consisted of restoring the hydro-

electrolyte balance by the administration of intravenous solutes, the administration of analgesics nonsteroidal anti-inflammatory drugs and antibiotics. Pleural drainage was intended to remove the effusion to suppress pulmonary and/or mediastinal compression. The pleural drain was placed in the 4th intercostal space on the anterior or middle axillary line and above the nipple line after an incision of about 2 cm at the lower costal margin under local anesthesia. The strapping (tape restraint) was performed in patients with unstable rib fractures.

The evolution was described as favourable in all patients who had been discharged with clinical and para-clinical improvement after treatment and unfavourable for a single patient who died from respiratory distress. The length of hospitalization was expressed in days and grouped into three [3] ranges (4-7d; 8-12d and 13 d).

## RESULTS

Over a 10-month period, we collected 30 cases of posttraumatic hemothorax out of a total of 187 hospitalized patients. The hospital frequency was 16%.

Men accounted for 80% (24 cases) of our sample and women for 20% (6 cases). The sex ratio was 4 in favour of men.

The average age of patients was 33.60 years with extremes of 3-70 years.

**Table I: Patient Age Distribution.**

Age Group	Frequency(N)	Percentage (%)
23 - 32	9	30
13 - 22	5	16.67
43 - 52	5	16.67
≥53	5	16.67
3 - 12	4	13.33
33 - 42	2	6.67
<b>Total</b>	<b>30</b>	<b>100</b>

**Average:** 33.60+/-19.12 years

**Extremes:** 3-70 years

Students and drivers were the most representative socio-professional layer (n = 6; 20%) followed by farmers, labourers, others (n = 3; 10%), merchants, housewives, tailors (n = 2; 6.67%), traders, accountants and security guards (n = 1; 3.33%).

The main events of posttraumatic hemothorax: was the AVP (n =15; 50%) and stabbing wounds (n =6; 20%)

**Table II: by occurrence circumstances.**

Occurrence	Frequency(N)	Percentage (%)
MVA	15	50
Stabbing	6	20
Fall from its height	4	13.33
Gun assault	2	6.67
Sports accident	2	6.67
Workplace accident	1	3.33
<b>Total</b>	<b>30</b>	<b>100</b>

Standard chest radiography was systematic as shown in Table III.

**Table III: Distribution by Chest X-ray Performed.**

Imaging	Frequency(N)	Percentage (%)
Rx thx de Face	29	96.67
Rx of the costal grill	25	83.33
Rx thx de Profil	1	3.33

Hemothorax was variable in abundance as shown in Table IV

**Table IV: by hemothorax abundance.**

Abundance	Frequency(N)	Percentage (%)
Petite Abondance	17	56.67
Medium Abundance	7	23.33
Great Abundance	6	20
TOTAL	30	100

The associated chest lesions have been shown in Table V.

**Table V: Distributions by Associated Lesions.**

Associated Lesions	Frequency(N)	Percentage (%)
Costal fractures	14	46.67
Abdominal traum	4	13.33
Cranial traum	3	10

The evolution was considered favorable in 29 patients (n=97%); among its patients a single patient developed a complication type of pyothorax (n=3%)

The average length of hospital stay was 8.9 days with extremes of 4 and 17 days. Following the period of hospitalization shown in Table V, it was noted that the patients were authorized to leave before 8 days for 43.33% (n = 13).

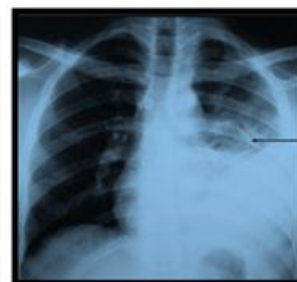
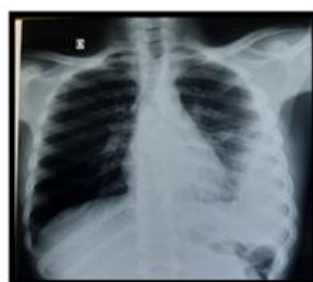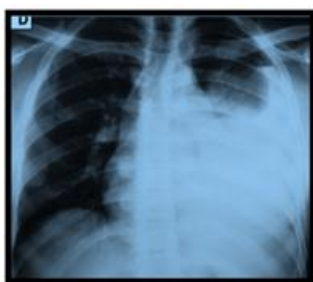**Table VI: by length of hospitalization.**

duration of hospitalization	Frequency(N)	Percentage (%)
8-12	13	43.33
4-7	11	36.67
≥13	5	20
Total	30	100

Moyenne : 8.96+/-3.57

Extrêmes : 4-17

Iconography:



Pleural drain at J3 post drainage

This is a patient of 35 years old workers received in the department of thoracic surgery for posttraumatic hemothorax following a AVP in which the digitized chest radiograph face was performed which highlighted: Homogeneous opacity of dense water tone filling the left costo-diaphragmatic cul-de-sac occupying the base of the left lung with concave upper limit inside occupying nearly half of the left hemithorax.

#### Medium Abundance Posttraumatic Hemothorax

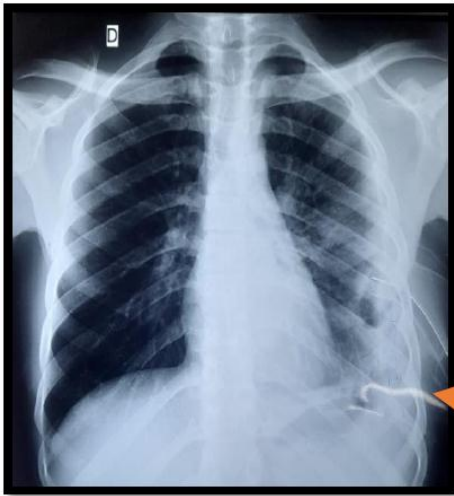
Standard chest x-ray of the same 35-year-old patient's face at J3 post-drains. Showing a drain in place with progressive return of the lung.

It is a patient of 18 years received in the department of thoracic surgery for posttraumatic hemothorax following an aggression by white in which the digitized chest

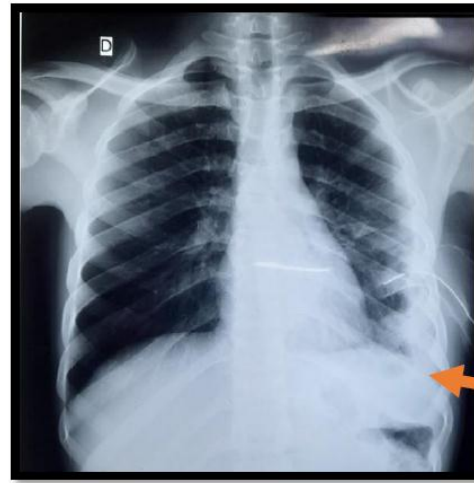
radiograph of face has been carried out that has evidenced opacity homogeneous of basal fluid tonality dense filling the cul-de-sacleft costo-diaphragmatic bag

with oblique upper limit inside occupying almost half of the left hemithorax.

**Medium Abundance Posttraumatic Hemothorax**



Pleural drain at J5post drains

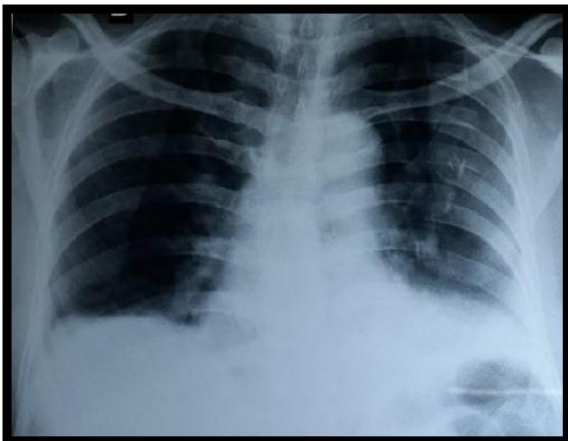

Pleural drain at J8 post drains

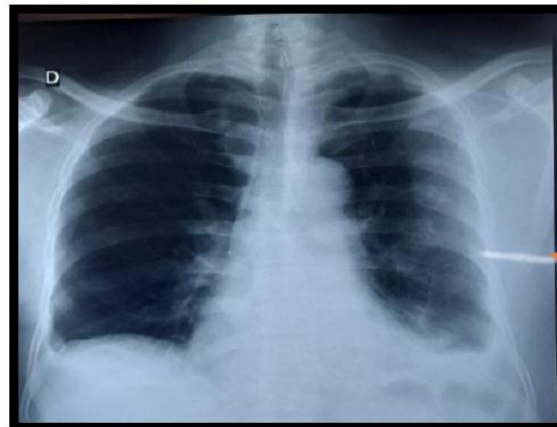
Standard chest x-ray of the face of the same 18-year-old patient at J5 post-drains. Showing a drain in place with progressive return of the lung.

Standard chest x-ray of the face of the same 18-year-old patient at J8 post-drainage. Showing a curved drain in place with a return of the lung followed by removal of the drain.

This is a 50-year-old grower patient admitted to the thoracic surgery department for posttraumatic hemothorax following a stroke in which the digitized chest X-ray face was performed which highlighted



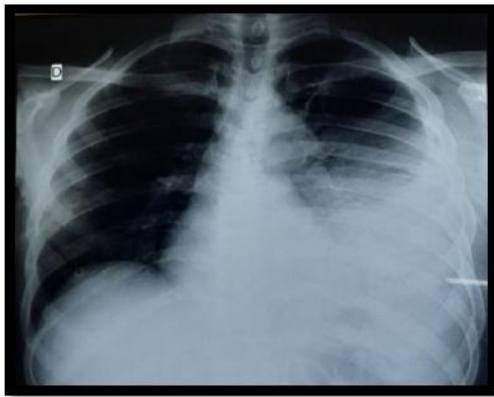
A blunting of the left costo-diaphragmatic cul-de-sac with multicostal fracture staggered from the 3rd to the 7th rib of the left hemithorax.



Pleural drain at J10 post drains

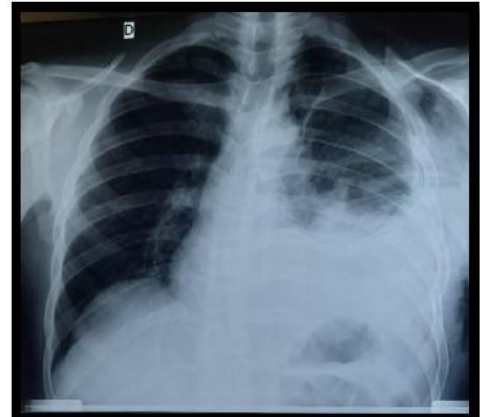
Standard x-ray of the control face chest of the same 50-year-old patient at J3 of observation. Showing a gradual return of the lung.

This is a patient of 35 years driver admitted to the department of thoracic surgery for posttraumatic hemothorax following a AVP in which the x-ray of the front digitized thorax was carried out which highlighted



Drain  
pleural à  
j4 post

Homogeneous opacity of dense water tone filling the left costo-diaphragmatic cul de sac occupying the left lung with concave upper limit inside occupying more than half of the left hemithorax.



Standard x-ray of the control face chest of the same 35-year-old patient at J4 post- drainage. Showing a drain in place with progressive lung re-expansion.

## DISCUSSION

The hospital frequency of hemothorax was 16% our results are different to those found by Camara A. K et al.<sup>[1]</sup> in Guinea in 2014 reported a hospital frequency of 9.25% of posttraumatic hemothorax. And comparable to those found by Macleod et al.<sup>[10]</sup> In Atlanta in the United States in 2010 had reported a 21% frequency of traumatic hemothorax retained. This increase could be explained by the increase in public road accidents, attacks by knives and firearms. The male sex was the most dominant in our study: 80% versus 20% of the female sex with a sex ratio 4. Our results are comparable to those found by Camara A. K et al.<sup>[1]</sup> in Guinea in 2014 which reported a male predominance with a frequency of 81.19% against 10.81% of women with a sex ratio of 8.5 in favor of men. Ahmad. T et al.<sup>[11]</sup> Karachi in Pakistan in 2013 found a male predominance of 82.7% This male predominance could be explained by the place of man in our society: exposure to workplace accidents, daring behaviours on motorcycles and driving. They are also the most vulnerable to physical violence and vice.

The average age of our patients was 33.60 +/- 19.12 years with extremes of 3-70 years. The 23-32 age group was the most represented at 30% of cases. Our results are comparable to those found by Scott M.F et al.<sup>[12]</sup> in 2015 in Berlin had reported an average age of 42.3 years with extremes from 3 to 93 years. This high frequency in young adults could be explained both by the hyperactivity of this young population and the behaviour of the subjects in the face of risky work (emotion, aggression) and not controlling their environment.

Pupils/students and drivers were the socio-professional groups most affected, 20% followed by workers with a proportion of 10%. Our results are comparable to those reported by Camara A K et al.(1) in Guinea in 2014 reported a high frequency among workers (37.84%) and (16.22%) students. This high frequency is due not only to

the risks associated with these professions, but to the fact that, in our context of socio-political crisis, students and drivers most often use vehicles for their travels; therefore much more exposed to the vital risks associated with road accidents.

Road accidents were the main causes in our study: 50% followed by stabbing or 20%. Our results are comparable to those found by Camara A. K et al.<sup>[1]</sup> in Guinea in 2014 had a frequency of 43.24% of road accidents. M.L. Bah et al.<sup>[13]</sup> in Guinea in 2017, which reported in their studies a frequency of 70% of public road accidents. This high frequency of public road accidents finds its explanation by the insufficient maintenance of the road network also by the ignorance of safety rules by the majority of the population.

Costal fractures were the most dominant associated lesions in our study at 46.67% followed by abdominal fractures at 13.33%. These results differ from those found by Camara A K et al.<sup>[1]</sup> in Guinea in 2014 who reported in their studies that trauma to the limbs were the most common lesions, at 35.13%, followed by oral lesions with 16.22%. Dubose J. et al.<sup>[14]</sup> in 2012 in California who reported in their studies 54.1% of costal fractures and 14.1% of abdominal-diaphragmatic lesions associated. These could be explained by the fact that hemothorax often occurs in a context of polytrauma. Analgesics and antibiotics were the most widely used medical treatment being 100% followed by anti-inflammatory drugs with 96.67% and 80% of PPIs. Our results are comparable to those found in Camara A K et al.<sup>[1]</sup> in Guinea in 2014 who reported in their studies that medical treatment consisted in giving painkillers, antibiotics and anti-inflammatory drugs. This wide use could be explained by the fact that it is a painkiller well known by practitioners, available, accessible and with lesser side effects compared to other painkillers; Pleural drainage was 43.33% followed by 20% trimming in

surgical treatment. Our results are comparable to those found by Bah M L et al<sup>[13]</sup> in Guinea in 2017 who reported in their studies a frequency of 47.22%. This low rate of thoracic drainage is explained by the fact that low-abundance posttraumatic hemothorax was the most dominant in our study.

The evolution was favorable in our study 97% against 3% of a complication type of pyothorax and lamented a case of death (3.33%) related to the complication in a respiratory distress chart our results are comparable to those found by Camara A K et al.<sup>[1]</sup> in Guinea in 2014 who reported in their studies a frequency of 97.30% of the evolution, and a case of death (2.70%) related to a failure to manage. These could be explained by the fact that the patients received effective management in the service and that the vital prognosis was not engaged.

The length of hospitalization of 8-12 days was the most dominant in our study: 43.33% followed by 4-7 days or 36.67% with an average of 8.96+/-3.57 days and extremes: 4-17 days. Camara A K and Coll. in Guinea in 2014<sup>[1]</sup> reported a length of hospitalization of 7 days or a frequency of 48.65%. The much shorter length of hospitalization in our study could be explained by the fact that the majority of our patients had a small amount of post-traumatic hemothorax.

## CONCLUSION

Posttraumatic hemothorax although uncommon observation is a concern at the Donka National Hospital Thoracic Surgery Department. They constitute a medical-We found that patients admitted to the thoracic surgery department of Donka UHC, in whom the diagnosis of posttraumatic hemothorax is established, are relatively young and mostly male. They are mostly in the formal sector and come mainly from the urban area. Stroke is the main circumstance of posttraumatic hemothorax events. Standard chest x-ray is the primary diagnostic method. Thoracic drainage is the fundamental gesture in its management in the absence of complications.

## REFERENCES

1. Camara AK, Magassouba AS, Naby CS, Sara A, Koghomou NA, Barry FM. Prise en charge des hemothorax post-traumatiques. Une expérience unicentrique de l'hôpital national Donka A propos de 37 cas. *Med Afr Noire* 2014; 61(8/9): 430-4.
2. Simonoviez P, Leone M, Albanèse J. Imagerie du thorax en réanimation traumatologique : Département d'Anesthésie -Réanimation. *Rev Int Sc Méd* 2009; 9: 929-37.
3. Metge L, F. Minvielle, T. Le Bivic, D. Jeanbourquin. Traumatismes fermes du thorax. *Journal de Radiologie* 2017; 8(6/5): 1-8.
4. Barry FM. Traumatismes fermés du thorax : épidémiologie et traitement au service de chirurgie thoracique de l'Hôpital National Donka. Thèse de médecine, N°125. Conakry: UGANC; 2006.
5. Camara N'F. Prise en charge des pneumothorax à l'Hôpital National Ignace Deen. Thèse de doctorat en médecine n°67/2001.
6. Djigne T.A. Hémothorax post-traumatique : fréquence, prise en charge et complication au service de chirurgie viscérale de l'Hôpital National Donka. Thèse de doctorat en médecine N°167/B Conakry : UGANC ; 2006.
7. Boersma WG, Stigt JA, Smit HJM. Treatment of haemothorax. *Respir Med.*, 2010; 13(11): 1-13.
8. Diallo C. Les traumatismes thoraciques au CHU-YO de 2005 à 2007 : Aspects épidémiologiques, cliniques et thérapeutiques au service de chirurgie générale et digestive : A propos de 168 cas. [Ouagadougou]: Thèse de médecine N°181; 2008.
9. Baccialone J, Jeanbourquin D, Montaigut Jy. Procédures diagnostiques des traumatismes non-vasculaires du thorax. In : Plaies et traumatismes du thorax. Ed. Arnette, Paris 1997; 215-216.
10. Macleod JB, Ustin JS, Kim JT, Lewis F, Rozycki GS, Feliciano DV. The Epidemiology of Traumatic Hemothorax in a Level I Trauma Center: Case for Early Video-assisted Thoracoscopic Surgery. *Eur J Trauma Emerg Surg.*, 2010; 36(3): 240-6.
11. Tanveer A, Ahmed SW, Soomro NH, Sheikh KA. Thoracoscopic evacuation of retained post-traumatic hemothorax. *J Coll Physicians Surg--Pak JCPSP.* 2013; 23(3): 234-6.
12. Scott MF, R. A. Khodaverdian<sup>1</sup>, J. L. Shaheen A. L. Ney R. M., Nygaard. Predictors of retained hemothorax after trauma and impact on patient outcomes. *Eur J Trauma Emerg Surg.*, 2015; 5/6: 1-6.
13. Bah ML, Camara Ako, AA B, AS M. Traumatisme fermé du thorax : aspects épidémiologiques et prise en charge au chu de Conakry / Thorax Farm Trauma : Epidemiological Aspects And Management In The Teaching Hospital of Conakry. *Rev Int Sc Méd -RISM* 2017; 5: 52-6.
14. DuBose J, Inaba K, Demetriades D, Scalea TM, O'Connor J, Menaker J, et al. Management of post-traumatic retained hemothorax: A prospective, observational, multicenter AAST study. *J Trauma Acute Care Surg* 2012; 72(1): 316-7.