

**ABDOMINAL DISTENSION REVEALING A SACRO COCCYGIAN CYSTIC  
TERATOMA IN A NEWBORN ABOUT A CASE****Kaukone R. A.<sup>\*1</sup>, Bizimana W.<sup>2</sup>, El Haddad S.<sup>3</sup>, Allali N.<sup>4</sup> and Chat L.<sup>5</sup>**<sup>1</sup>Résident De Radiologie Hôpital Mère Et Enfant Rabat.<sup>2</sup>Résident De Radiologie Hôpital Mère Et Enfant De Rabat.<sup>3</sup>Professeur Assistant De Radiologie Hôpital Mère Enfant De Rabat.<sup>4,5</sup>Professeur De Radiologie Hôpital Mère Et Enfant De Rabat.**\*Corresponding Author: Kaukone R. A.**

Résident De Radiologie Hôpital Mère Et Enfant Rabat.

Article Received on 21/07/2022

Article Revised on 11/08/2022

Article Accepted on 31/08/2022

**ABSTRACT**

Sacro coccygian teratomas (SCTs) are rare congenital tumors, although they are most common in the neonatal period. The revealing clinical picture is variable. It may be hydramnios before birth, a sacral or gluteal mass at birth, or signs of urinary or digestive compression later. When faced with a sacrococcygeal mass, CT and MRI can suggest the diagnosis. Tumor excision is the only effective treatment for SCT. The pathological study confirms the diagnosis. A therapeutic complement by chemotherapy is essential in the aligned forms. The prognosis for SCT is generally good. Indeed in benign teratomas, early and total surgery removing the coccyx gives good results. The prognosis for malignant teratomas has improved markedly with chemotherapy. Postoperative, clinical, biological and radiological monitoring looking for sequelae and recurrence. We report this study in order to illustrate the rarity and highlight the clinical radiological and therapeutic rarity and evolution of this condition for our patient the treatment consisted of radical cyst surgery and sacrectomy.

**KEYWORDS:** Sacro Coccygian Teratoma – New Born – Ultrasound – Ct – Mri.**INTRODUCTION**

Different types of masses can affect the presacral area in children and be congenital, developmental, or inflammatory. The mass can have neural, vascular, lymphatic or mesenchymal origins and can be primary (as in focal disease) or systemic (as in multifocal disease).

Since the clinical manifestations of pre-sacral masses are often nonspecific, imaging plays an important role in the detection, differentiation of these masses, and surgical planning. For these reasons, it is important for radiologists to know the anatomy of the presacral region in children for an accurate interpretation of the results.<sup>[1]</sup>

These masses can be cystic in infants and can pose a risk of superinfection, inflammatory episodes, fistulas, malignant degeneration and recurrence, requiring total surgical removal upon diagnosis.

We report the case of a retro-rectal cystic mass diagnosed incidentally at birth in front of an increase in abdominal volume. We will discuss the aspect in imaging, in particular CT and MRI ultrasound.

**OBSERVATION**

This is Nadia's daughter who is at D0 of life and whose history shows an unsuccessful pregnancy and then an uncomplicated vaginal birth. She was referred by the pediatric emergency department for exploration of an abdominal distension discovered incidentally at birth.

Ultrasound revealed a large retro-rectal abdomino-pelvic mass, unilocular, well defined, without septum, buds or calcification, pure anechoic, communicating with the medullary canal by a fine channel.

Abdominal CT revealed an abdomino-pelvic mass with a pure fluid density of 12 HU, well limited with a thin wall, without septum, bud or calcification, not enhanced at the periphery after injection of contrast product. Topographically, this cystic mass comes into contact with the sacral spine, the coccyx, seeming to communicate with the medullary canal through a fine channel. Laterally, it comes into contact with the primary iliac vascular axes which remain permeable. Forward, it pushes the colon, the small intestine and the bladder down. It exerts an important mass effect on the sigmoid recto with moderate distension of the loops upstream. Associated with it is a thin blade of peritoneal effusion. It measures 166 x 90 x 66 mm.

## DISCUSSION

The retro-rectal space is limited in front by the pre-rectal fascia, behind by Waldeyer's pre-sacral fascia, laterally by the pelvic wall with its fascia below by the levator ani muscle and above by the peritoneal deflection in view. of the intervertebral disc.<sup>[1]</sup> The presacral space contains a variety of fat tissue including mesenchymal tissue lymph nodes, nerve plexuses and vessels.

However, masses that occur in underlying regions such as the sacrum, muscle and ovaries can extend into the presacral space.<sup>[2]</sup>

The anatomical pathology of the surgical specimen revealed a cystic teratoma. The pathological study confirms the diagnosis. It shows a tumor made up of somatic tissues, derived from the three layers ecto, endo and mesoderma. Immature teratomas are opposed to mature teratomas according to their degree of differentiation.

Cystic teratoma is a sacrococcygeal germ cell tumor secondary to disorganization of primitive totipotent neuronal cells during germline embryogenesis. It results from the differentiation of totipotent cells along the embryonic pathways.

It is the most common presacral germ cell tumor in children.<sup>[2,3]</sup> the prevalence of the benign form of sacrococcygeal teratoma is approximately one in 35,000 to 40,000 births, it accounts for 60% of all sacrococcygeal teratomas.

Most sacrococcygeal teratomas present as presacral or pelvic masses that are palpable on rectal examination. They can spread into the abdomen.

The anatomical classification of masses includes four groups:

Type I external masses with a small pre-sacred component

Type II external mass with a significant intra pelvic component

Type III external mass with pelvic and abdominal component

Type IV internal mass with intra pelvic and abdominal localization

About 50 and 70% of sacrococcygeal teratomas appear in the first days of life and 80% before the age of six months, less than 10% are diagnosed after the age of 2 years.

75% of children with sacrococcygeal germ cell tumors are female

### Antenatal Diagnosis.<sup>[4,5,6]</sup>

Advances in ultrasound and fetal medicine currently make it possible to recognize this pathology during pregnancy, but also to specify certain prognostic factors

in order to provide better information to the couple. Prenatal knowledge of these TSCs also makes it possible to ensure better obstetrical follow-up and, finally, to plan the delivery in a specialized structure where the newborn will be entrusted to the pediatric and surgical team.

### Fetal ultrasound

Malformation can be motivated by a clinical abnormality of the pregnancy (hydramnios, threat of premature delivery). The diagnosis can be made from 16 WA especially thanks to the more precise endovaginal examination; most often, it is posed by the morphological assessment of 22 SA (with an average discovery term of 26.4 SA) or by the existence of a hydramnios or signs of hydrops.

### She permits

- Appreciate the size of the tumor and its dynamic growth
- To specify its solid or mixed cystic nature
- To look for the presence of calcifications of intra-tumor hemorrhage or necrosis
- To appreciate the intra pelvic extension
- To make the differential diagnosis
- Look for malformations and associated complications
- Evaluate the prognosis
- And finally to orientate towards the mode and time of delivery
- Doppler examination makes it possible to appreciate the importance of tumor vascularization

### Diagnostic criteria

**Tumor syndrome** with mass hanging from the distal end of the more or less heterogeneous sacrum contained mixed with hypo and hyperechoic areas, irregular borders with cystic components and sometimes calcifications.

Sometimes it is a very limited tumor with hypoechoic content, sometimes of a purely cystic appearance, sometimes of a mixed component.

Extrinsic homogeneous anorectal compression

A normal lumbosacral spine.

**Vascular signs;** a very enlarged middle sacral artery (risk of intra-tumor hemorrhage)

### Arterialization (color doppler)

An increase in the caliber of the inferior vena cava measured just as it enters the right atrium (normal is 2.9 to 4 mm between 21 and 29 WA and possibly an increase in flow in the descending aorta

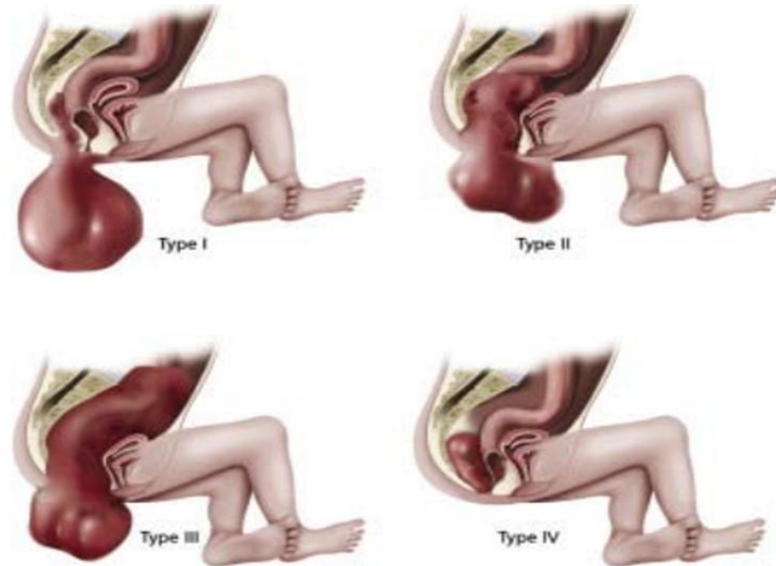
### FETAL MRI

A study on fetal MRI is more and more frequent with the benefit of no risk of fetal exposure to the magnetic field IRM can provide additional information and can:

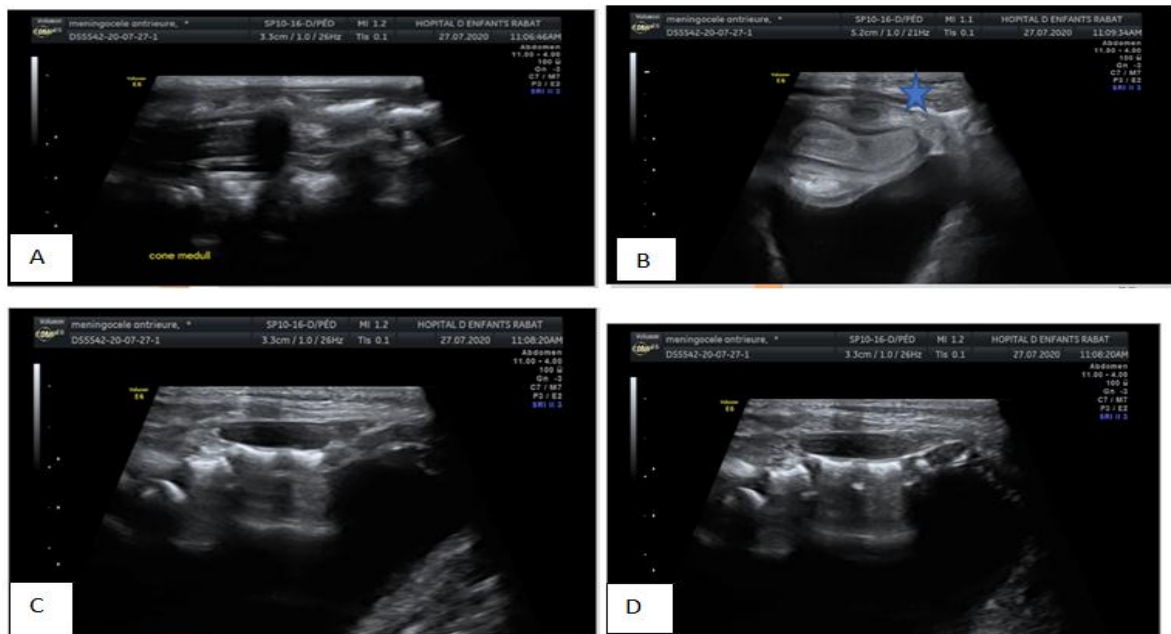
- Better assess the size of the tumor
- Specify the nature of the tumor when the ultrasound cannot be
- Check for the existence of intra-tumor hemorrhage
- Appreciate the intra pelvic or intraspinal extension
- Study the relationship with neighboring structures

The HASTE 5half fourier single shot turbo spin echo acquisition sequence is weakly sensitive to motion artefacts which allows high resolution images to be obtained.

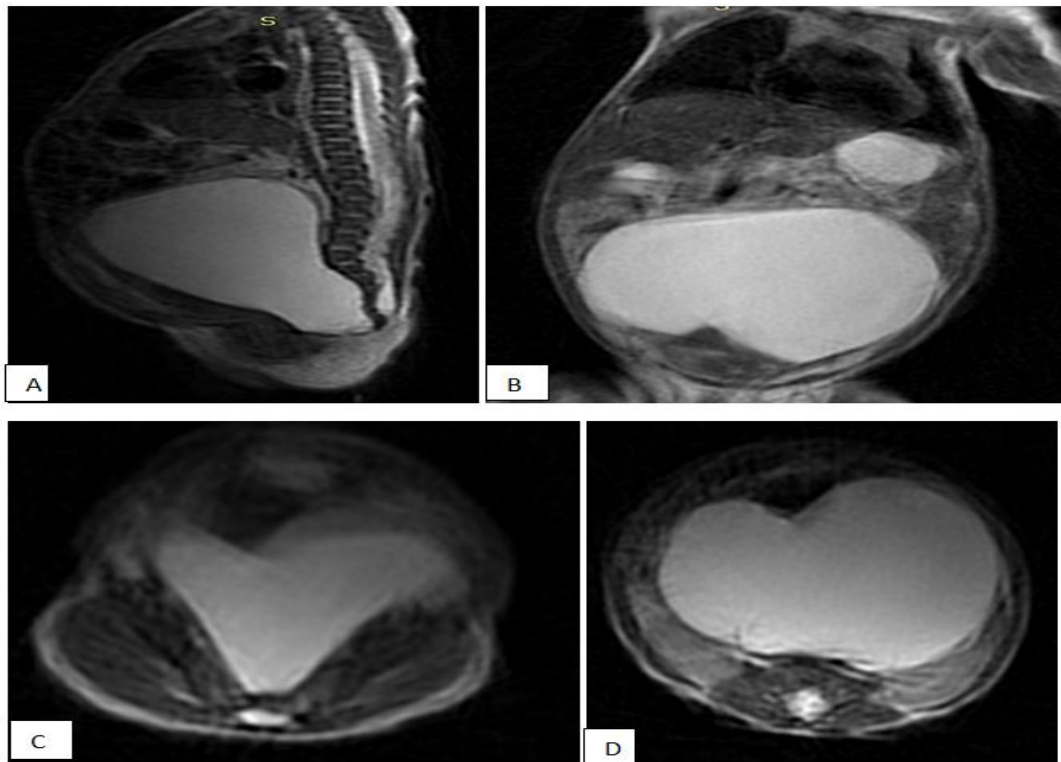
MRI gives better contrast between solid and cystic components of teratoma



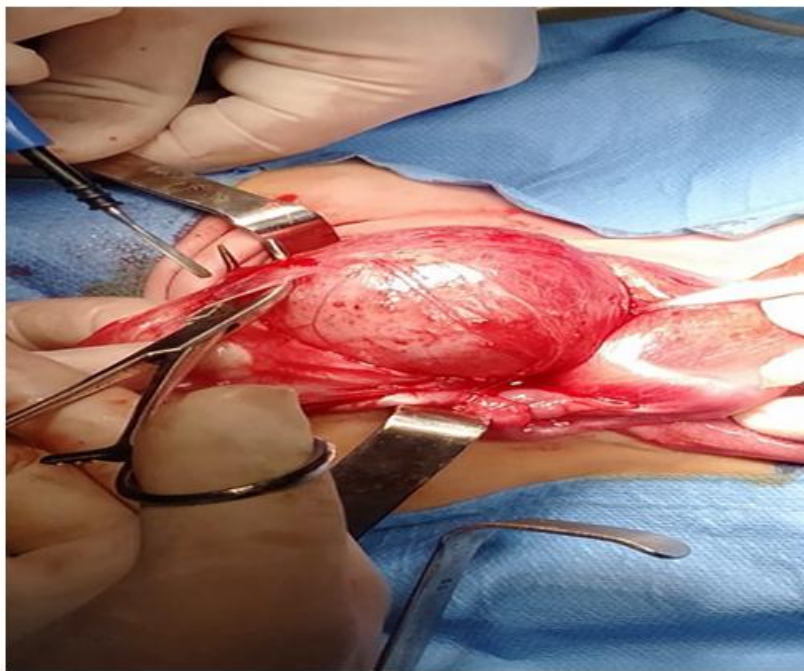
Classification of American academy of pediatric surgical section survey (AAPSS) selon ATMAN



Longitudinal CUTS A C D  
 THE MEDULLARY CONE A  
 MEDULAR ECHOGRAPHY C and D LOW WITH PURE ANECHOEGE CYSTIC MASS WITHOUT PARTITIONS NOR CALCIFICATION NOR ENDOKYSTIC VEGETATION SEEMING TO COMMUNICATE THROUGH A PERTUIS WITH THE MEDULLARY CANAL. AXIAL SECTION B ON VISUALIZES THE RECTUM (R) AND THE UTERUS BEHIND THE CYSTIC MASS AND THE BLADDER IN FRONT.

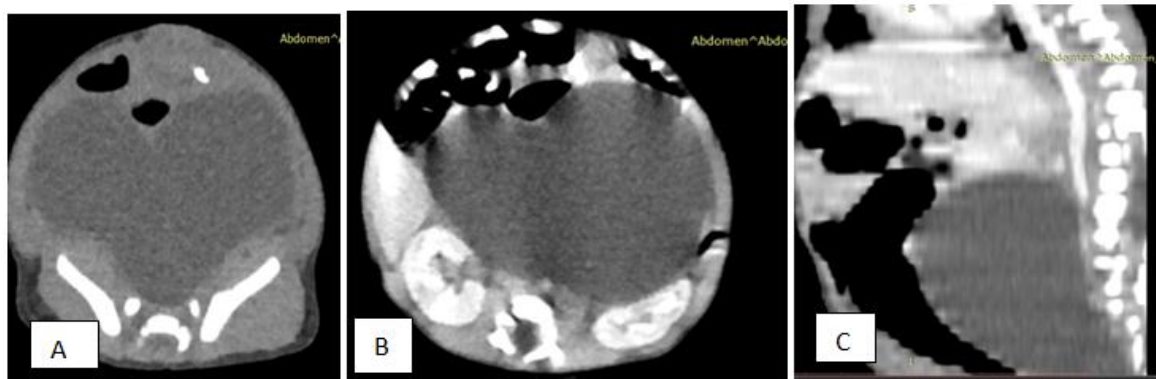


T2 MRI IMAGE AXIAL B C D AND SAGITAL A SECTIONS IN INTERMEDIATE HYPERSIGNAL



Intraoperative images of the retro rectal cystic mass





SCANNOGRAPHIC IMAGES AXIAL A and B AND SAGITAL C SECTIONS SHOWING A CYSTIC MASS OF LIQUID DENSITY WITHOUT PARTITION OR CALCIFICATION OR ENDOKYSTIC BUD.

### Post Natal Diagnosis

#### Circumstances of discoveries

Most TSCs are diagnosed or visible at birth: it is most often a mass visible in the middle sacrococcygeal region implanted on the sacrococcygeal region and seems to extend the child's trunk by deforming the gluteal region and perineum the latter is more or less distended. The anus is often pushed forward and the vulva is horizontal. Signs of compression.

The variable nature of the extension of TSC explains some late discoveries non-exteriorized tumors tend to extend upward and forward into the presacral space frequently producing signs of compression following displacement of the rectum and pelvic organs.

#### Associated malformations<sup>[7,8,9]</sup>

Sacral hypoplasia; absence of the last sacral vertebrae.

Spina bifida occulta; affects the first sacral vertebra, the other sacral vertebrae or the dorsolumbar spine, it may be accompanied by a meningocele or a myelomeningocele.

The other abnormalities are defects in segmentation or anterior fusions of the vertebrae, hypoplasia of the posterior arch.

Uro genital anomalies urinary and / or genital duplication, vaginal stenosis, hypospadias, epispadias extrophy bladder cryptorchidism renal agenesis.

Intestinal malformation Intestinal duplication.

Cardiac malformations persistence of the ductus arteriosus, transposition of the great vessels, valve pathology inter ventricular communication.

The objective of imaging is to achieve the localization and extent of the tumor by fetal ultrasound fetal MRI with rapid sequences allow prenatal detection to assess fetal anatomy, prenatal diagnosis of TSC involves a high

risk of preterm birth as well as higher mortality and morbidity due to hydrosy; bleeding and rupture of the lump.

Benign teratomas contain only mature tissue including fat fluid, calcification and a small amount of soft tissue, predominantly cystic tumors are likely benign, presence of amount of immature tissue in a teratoma suggests potential malignant and the possibility of a local recurrence.

On pre and postnatal ultrasound shows cystic masses are anechoic with internal areas of echogenicity due to fat or debris.

CT and MRI allow surgical planning to allow initial diagnosis and monitoring and local recurrence.

On CT, benign teratomas are predominantly cystic and have a density similar to fluids on CT and may include bone, fat, and calcification.

ON T1-weighted MRI IMAGES fat tissue areas show high signal intensity on T1-weighted images while bone calcification is shown as signal void areas.

The tailbone is still involved even in benign sacrococcygeal teratoma and must be resected with the tumor

Malignant teratomas have a predominantly solid component, and frequent bleeding and necrosis can metastasize or spread into major structures such as the spine or gluteal muscles.

Alpha fetoprotein is elevated in 50% of malignant teratomas

#### Differential diagnosis<sup>[10]</sup>

Due to the lower frequency of pure pre-sacral forms, it arises mainly with other tumors of the caudal end of the fetus.

For cystic forms, it will essentially be a question of eliminating a meningocele, by the meticulous study of the lumbosacral portion of the spine, in search of a spina bifida, and the study of encephalic structures (in particular of the posterior cerebral fossa); as well as lower limb movement and bladder emptying.

The other solid tumors in the region have a very similar echostructure, but fortunately they are even rarer (hamartoma, giant cell tumor of the sacrum, mucoid carcinoma, coccygeal sarcoma and glioma).

The differential diagnosis of sacrococcygeal teratomas with exclusive endopelvic prolongation will essentially arise in cystic forms, with other intra-abdominal cystic masses

#### **Obstructive Uropathies**

- Digestive obstructions or duplications
- Cystic lymphangioma
- Ovarian cyst in female fetuses

#### **Processing Antenatal care**

The management of severe fetal pathologies, such as hypervascular TSC, requires multidisciplinary collaboration between obstetricians, radiologists, cardiopediatricians, neonatologists, anesthesiologists and pediatric surgeons.

Antenatal care is essentially based on rigorous obstetric monitoring.<sup>[11]</sup>

#### **Postnatal surgical management**

Abdominal development beyond the S3 root requires an isolated or combined abdominal approach, simultaneous or delayed.<sup>[12-13]</sup>

The laparoscopic route is inappropriate for this type of lesion. The excision must be done in full. For benign tumors, the sequelae after surgery are rare, because the dissection is facilitated by a natural pericystic cleavage plan; the risk is above all that of local recurrence occurring in 10 to 15% of cases.

In degenerated tumor, metastases are frequent in monobloc because of the risk of recurrence when incomplete.<sup>[12-13]</sup>

#### **Medical care**

According to the indications of the French society of pediatric oncology.<sup>[14]</sup>

Mature and immature non-secreting TSCs:

They are operated straight away. Surgery is the essential therapeutic means. It must be started as early as possible and must include a total excision of the mass carrying the coccyx. In case of total excision, no additional treatment is necessary.

#### **The Prognosis<sup>[15]</sup>**

##### **AGE**

The prognosis for TSCs diagnosed after birth is generally good. It depends on According to Altman et al. ] the percentage of malignancy, as well as the mortality rate, are higher in the event of a diagnosis delayed beyond 2 months.

##### **Tumor Size**

According to Altman et al.<sup>[11]</sup> the death rate is higher in cases of large TSC. Indeed, the hemorrhagic risk increases in the most voluminous forms.

##### **Histological Nature**

Mature TSCs with a predominantly cystic component have a good prognosis compared to solid immature TSCs.

Malignant TSCs are the most to be feared (Table XXXV), although the prognosis is markedly improved with polychemotherapy followed by complete resection.

##### **Anatomical Type**

Type I and II TSCs are rarely malignant, as they are most often discovered at birth or even prenatal, given the exteriorization of the tumor, and therefore quickly excised. On the other hand, type III and IV TSCs are often diagnosed late with a higher risk of malignancy and distant metastases. Their prognosis is worse

#### **CONCLUSION**

SACRO COCYGIAN TERATOMS (SCTs) are rare congenital tumors, CT and MRI can suggest the diagnosis. Tumor excision is the only effective treatment for TSC. A therapeutic complement by chemotherapy The prognosis of TSC is generally good. Postoperative, clinical, biological and radiological monitoring looks for sequelae and recurrence.