

ROLE OF LEECH THERAPY IN CHRONIC VENOUS ULCER- A CASE STUDY

Dr. Ardra B. Thorat*

Assistant Professor, YAC PGT & RC Kodoli, Kolhapur, Maharashtra, India.

*Corresponding Author: Dr. Ardra B. Thorat

Assistant Professor, YAC PGT & RC Kodoli, Kolhapur, Maharashtra, India.

Article Received on 02/09/2019

Article Revised on 23/09/2019

Article Accepted on 14/10/2019

INTRODUCTION

Venous disease is responsible for 60 to 70 percent of all ulcers in the lower limb. Venous ulcers (stasis ulcers) are wound that are thought to occur due to improper functioning of venous valves usually of the legs. The exact pathophysiology of ulcer development has not been established, but they are thought to arise when venous valves that exist to prevent backflow of blood do not function properly, causing the pressure in veins to increase. The body needs the pressure gradient between arteries and veins in order for the heart to pump blood forward through arteries and into veins. Venous hypertension may also stretch veins and allow blood proteins to leak into the extra vascular space; isolating extracellular matrix (ECM) molecules and growth factors preventing them from helping to heal the wound leakage. Originally it was thought that static blood within the superficial veins led to hypoxia, which causes tissue death and this was not confirmed by investigation of venous oxygen saturation.^[1]

On the micro-vascular level there is alteration and distension of the dermal capillaries with leakage of fibrinogen into the tissues; polymerization of the fibrinogen into fibrin cuffs leads to peri-vascular cuffing that can impede oxygen exchange thus contributing to ulceration.^[2]

Now a day's treatment available for venous ulcer is compression therapy; although the best method to achieve it remains controversial. Wound care in these patients focuses on maintaining a moist wound environment.^[3] Zinc oxide impregnated, non-elastic bandage (four layered bandage) approach as a more optimal method of obtaining graduated compression.^[4] Unfortunately recurrences are frequent in spite of preventive measures.^[5]

Therefore in these conditions the patient was treated with leech therapy.^[6] once in a week with *Parishek* of *Rakt shodhak dravya Kashay* along *Kaishor Guggulu* 500 mg one BD for 30 days. This treatment is found to be helpful in relieving vascular congestion. It can be effectively used in long standing venous ulcers.

Case Study

A. Personal details

1. Age and Sex of Patient- 41 year male
2. Occupation- standing job 8 hours a day
3. Addiction – No any addiction like smoking-drinking- alcohol and tobacco chewing.
4. Built- medium
5. Diet – mix
6. Sleep- adequate at night 7 hours.

7. Short saphenous varicosity since last 15 years.
8. Ulcer over left leg above lateral maleolus since last 10 years.
9. No history of Rheumatoid arthritis-Osteoarthritis-Tuberculosis
10. Treatment history- No specific treatment for any other disease. He has taken allopathic medicines for his ulcer but can not get relief.

B. General Examination

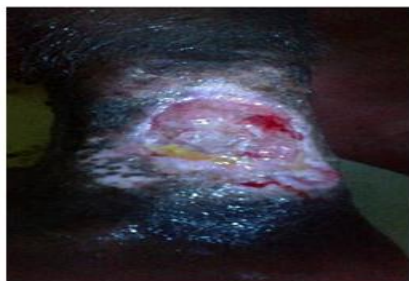
1. R.S.- clear, air entry equal on both side
2. CVS- S1, S2 heart sounds normal, no added sounds
3. CNS- Conscious, oriented
4. P/A- Soft, No tenderness

C. Local Examination

1. Site of ulcer- left leg dorso- lateral aspect above the lateral maleolus
2. Size- ~ 15 x 10 cm
3. Margin – shallow, irregular.
4. Edge- gently sloping edge.
5. Discharge- Exudate and slight serous discharge.
6. Surrounding skin- Blackish discoloration i.e. lipodermatosclerosis and indurated pigmented skin with eczema and dermatitis, indicates chronic ulcer.
7. Floor of the ulcer—It contains granulation tissue covered by variable amount of adherent slough and exudate
8. Tenderness -present.
9. Dorsalis pedis pulsation- Palpable.

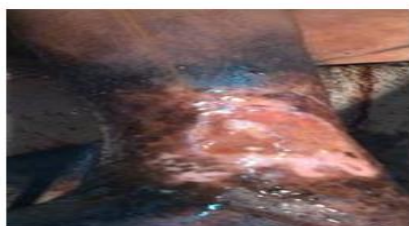D. Investigations

1. His left leg venous Color Doppler study shows that– Incompetent sapheno femoral junction & popliteal shunt saphenous junction at both side.
2. Biopsy sample taken from ulcer edge- biopsy to exclude the marjolin's type of ulcer. The report was not significant.
3. BSL random – 124mg/dl

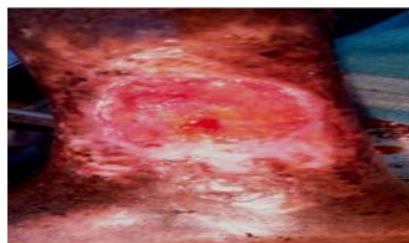


Day 1. The Ulcer shows unhealthy tissue at its floor with surrounding blackish discoloration.

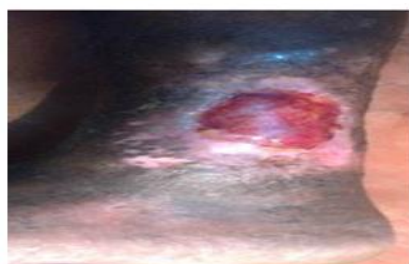
Size ~ 15 cm x 10 cm



Day 10- The peripheral blackish discoloration minimizes.



Day 20- the floor of wound shows some healthy granulation tissue. Slough decreases



Day 30 - the size of the ulcer reduces 3cm x 4cm. ulcer edge is slopping showing tendency towards healing. No slough and discharge.

The constituents present in the saliva of Leech are^[7,8,9]

1. **Bdellins** = Anti-inflammatory effect and inhibits trypsin, plasmin and acrocin.
2. **Hyaluronidase** = for penetration and diffusion of pharmacologically active substances into the tissues, has antibiotic properties. Increases interstitial viscosity.
3. **Hirudin** = (a potent anticoagulant); Enables the blood to flow for some time without clotting. It inhibits blood coagulation by binding to thrombin.
4. **Calin** = Inhibits blood coagulation by blocking the binding of the Von Willebrand factor to collagen and can last upto 12 hours.
5. **Eglins** = Anti-inflammatory. Inhibit the activity of alpha-chymotrypsin, chymase, subtilisin, elastase, cathepsin G
6. **Destabilase** = Dissolves fibrin and has thrombolytic effects.
7. **Carboxypeptidase's** = A inhibitors Increases the inflow of blood at the bite site
8. **Acetylcholine** = Vasodilator
9. **Histamine-like substances** = A vasodilator increases the inflow of blood at the bite site.
10. **Hirustasin** = Inhibits kallikrein, trypsin, chymotrypsin, and neutrophilic cathepsin G.

11. **Eglins** = Anti-inflammatory. They inhibit the activity of alphachymotrypsin, chymase, substilisin, elastase, and cathepsin G.
12. **Collagenase** = Reduces collagen.
13. **Complement inhibitors** = Replace natural complement inhibitors if they are deficient.
14. **Anesthetics substance** = Anesthetic action.
All these constituents help to treat the venous ulcer.

RESULT AND DISCUSSION

Mode of action of Leech

1. It relieves vascular congestion. So, can be effectively used in conditions like long standing venous ulcers, improves micro angiopathy hence helpful in venous ulcer.
2. It is used in this patient to relieve the pain, inflammation & discomfort symptomatically
3. *Ayurveda* believes that Leeches suck only the impure part of blood. We can assume the sucking of blood from superficial veins which is deoxygenated or impure one
4. Leech keeps up sucking of an impure stagnant blood which provides free flow to circulating blood and that leads to cure the disease improving blood circulation.
5. Leech can be applied in each external part of the body including the vital part (Marma) and also in aged, debilitated patients. Even deep seated impure blood can be taken out easily with the help of Leech.
6. *Kaishor Guggulu* is having *Tridoshnashak* and *Raktprasadak* property so it improves the blood circulation.
7. *Parishek* of *Raktprasadak Dravya* helps to remove adherent slough and helps to develop healthy granulation tissue.
4. Darwood RJ, Theivacumar N, Dellagrammaticas D, et al. Randomized clinical trial comparing endovenous laser ablation with surgery for the treatment of primary great saphenous varicose veins. *Br J Surg*, 2008; 95: 294.
5. Falanga V, Venous ulceration. *J Dermatol Surg Oncol*, 1993; 19: 764
6. Sushruta- Samhita Sutrasthan Dalhana's commentary, Chaukhambha Visvabharati oriental Publishers & Distributors Varanasi, edited & translated by Priyavrat Sharma, Reprint, 2013; 1: 135.
7. Eldor A, Orevi M, Rigbi M. The role of the leech in medical therapeutics. *Blood Rev*, 1996; 10: 201-209.
8. Glyova O. Modern Hirudotherapy — A Review. (Biotherapeutics, Education and Research Foundation). *The (Beter) Letter*, 2005; 2: 1-3.
9. Sollner C, Mentele R, Eckerskorn C, Fritz H, Sommerhoff CP. Isolation and characterization of hirustasin, an antistatin-type serine-proteinase inhibitor from the medical leech *Hirudo medicinalis*. *Eur J Biochem*, 1994; 219: 937-943.

CONCLUSION

Leech therapy along with *Kaishor Guggulu* and *raktprasadak dravya parishek* helps to improve the local blood circulation hence; healing is promoted and treats the venous ulcer.

ACKNOWLEDGEMENT

I express my sincere thanks to my guide Dr Ashutosh Kulkarni sir and Dr N. V. Borse sir ,my Institute and my *Shalyatantra* Department colleagues.

REFERENCES

1. Bailey & Love's Short Practice of Surgery 26th edition by CRC press NW, 2013; 917.
2. Schwartz's Principles of Surgery 9th edition, McGraw-Hill companies, 2010; 225.
3. Lurie F, Creton D, Eklof B, et al, Abbott RD, et al. The epidemiology study of endovenous radiofrequency obliteration (closure) versus ligation and vein stripping (EVOL VeS): two-year follow up. *Eur J Vasc Surg*, 2005; 29: 67