

**KNOWLEDGE AND AWARENESS OF ORAL MYIASIS AMONG DENTAL STUDENTS:
A QUESTIONNAIRE-BASED CROSS-SECTIONAL STUDY**

¹*Dr. Avika Pareek, ²Dr. Manoj Meena, ³Dr. Pallavi Baghla, ⁴Dr. Neha Laskar, ⁵Dr. Kanishka Singh, ⁶Dr. Aryan Agarwal, ⁷Dr. Tanishka Choudhary

^{1,6,7}Oral Medicine and Radiology PG 1st Year at Rajasthan Dental College Jaipur.

²Professor and Head Department of Oral Medicine and Radiology Rajasthan Dental College Jaipur.

³Reader Department of Oral Medicine and Radiology Rajasthan Dental College Jaipur.

^{4,5}Senior Lecture Department of Oral Medicine and Radiology Rajasthan dental College Jaipur.



*Corresponding Author: Dr. Avika Pareek

Oral Medicine and Radiology PG 1st at Rajasthan Dental College Jaipur.

DOI: <https://doi.org/10.5281/zenodo.19416322>

How to cite this Article: ¹*Dr. Avika Pareek, ²Dr. Manoj Meena, ³Dr. Pallavi Baghla, ⁴Dr. Neha Laskar, ⁵Dr. Kanishka Singh, ⁶Dr. Aryan Agarwal, ⁷Dr. Tanishka Choudhary. (2026). Knowledge and Awareness of Oral Myiasis Among Dental Students: A Questionnaire-Based Cross-Sectional Study. World Journal of Pharmaceutical and Medical Research, 12(4), 309–315. This work is licensed under Creative Commons Attribution 4.0 International license.



Article Received on 05/03/2026

Article Revised on 25/03/2026

Article Published on 04/04/2026

ABSTRACT

Background: Oral myiasis is a rare but potentially destructive parasitic infestation caused by dipterous larvae. Although uncommon, it is frequently reported in tropical and subtropical regions, especially among immunocompromised and debilitated individuals. Dental professionals play a crucial role in early diagnosis and management. **Aim:** To evaluate the knowledge and awareness of oral myiasis among dental students.

Objectives

1. To assess awareness regarding oral myiasis.
2. To evaluate knowledge of etiology, clinical features, and risk factors.
3. To assess awareness regarding diagnosis, prevention, and management.

Materials and Methods: A cross-sectional questionnaire-based study was conducted among undergraduate, postgraduate dental students and dental practitioners. A pre-validated structured questionnaire consisting of 15 close-ended questions was distributed through Google Forms. A total of 500 dental students participated in this study including third year, final year, interns, postgraduates and others like dental practitioners.

Results: Among 500 participants:

- 3rd year BDS: 82
- 4th year BDS: 84
- Interns: 105
- Postgraduates: 68
- Others: 161

Awareness levels varied, with clinical knowledge being higher among postgraduates compared to undergraduate students. **Conclusion:** Although general awareness exists, detailed clinical knowledge of oral myiasis among dental students requires strengthening. Inclusion of tropical oral diseases and opportunistic infections in undergraduate curricula is strongly recommended.

KEYWORDS: Oral myiasis, dental students, awareness, tropical infections, parasitic infestation.

INTRODUCTION

Myiasis is derived from the Greek word *myia* (fly) and *iasis* (disease).^[1] It refers to infestation of live human and vertebrate animals with dipterous larvae that feed on host tissues, body fluids, or ingested food.^[2] The condition was first described by F.W. Hope in 1840.^[1] Oral

myiasis, first reported by Laurence in 1909^[3], is a rare manifestation of this parasitic infestation.

Although cutaneous myiasis is more common, oral myiasis is comparatively rare due to the relatively protected nature of oral tissues.^[4] However, it is reported

more frequently in tropical and subtropical regions, particularly in developing countries such as India, Brazil, and Tunisia.^[5-7]

Predisposing factors include poor oral hygiene, advanced periodontal disease, oral malignancy, mouth breathing, neurological disorders, alcoholism, senility, and immunocompromised states.^[8-12] Dental professionals are often the first to encounter such cases, making awareness critical.

Despite its clinical significance, awareness among dental students remains inadequately explored. Hence, this study was conducted.

Oral tissues become susceptible when natural protective barriers are compromised. Predisposing conditions include:

- Advanced periodontal disease
- Poor oral hygiene
- Mouth breathing
- Senility
- Neurological disorders
- Oral malignancies
- Alcoholism
- Immunocompromised states.^[8-13]

India reports a significant proportion of oral myiasis cases, particularly among patients with advanced oral squamous cell carcinoma and debilitated geriatric populations.^[14-17]

Despite its rarity, oral myiasis can lead to extensive tissue destruction, bone erosion, osteomyelitis, and even life-threatening complications if untreated.^[18,19] Early detection is therefore critical.

Dental students represent future frontline clinicians. However, literature assessing awareness among dental students remains limited. Inadequate knowledge may

delay diagnosis, increase morbidity, and complicate management.^[20-23]

Therefore, this study was undertaken to evaluate knowledge and awareness regarding oral myiasis among dental students.

MATERIALS AND METHODS

Study Design

Cross-sectional questionnaire-based study.

Study Population

Dental students -Undergraduate (3rd year, 4th year), interns, postgraduate, others like dental practitioners.

Sample Size

Total 500 dental students

Inclusion Criteria

- Undergraduate and postgraduate dental students
- Students willing to participate

Exclusion Criteria

- Incomplete questionnaires
- Non-dental participants

Study Tool

A pre-validated structured questionnaire containing 15 close-ended questions assessing:

- Awareness
- Etiology
- Risk factors
- Clinical features
- Diagnosis
- Prevention
- Management

Data Analysis

Data were analyzed using descriptive statistics and expressed as frequency and percentage.

SPSS VERSION

			Year of study					Total
			3 rd year BDS	4 th year BDS	Intern	Other	Postgraduate	
Gender	Female	Count	54	50	72	111	43	330
		% within Year of study	65.9%	59.5%	68.6%	68.9%	63.2%	66.0%
	Male	Count	28	34	32	49	25	168
		% within Year of study	34.1%	40.5%	30.5%	30.4%	36.8%	33.6%
	Prefer not to say	Count	0	0	1	1	0	2
		% within Year of study	0.0%	0.0%	1.0%	0.6%	0.0%	0.4%
Total	Count	82	84	105	161	68	500	
	% within Year of study	100.0%	100.0%	100.0%	100.0%	100.0%	100.0%	

Out of the total 500 participants, 82 (16.4%) were from 3rd year BDS, 84 (16.8%) from 4th year BDS, 105 (21.0%) interns, 161 (32.2%) other category, and 68 (13.6%) postgraduate students. Females constituted the majority of the study population with 330 (66.0%) participants, while males accounted for 168 (33.6%) and 2 (0.4%) preferred not to disclose their gender. Among 3rd year BDS students, 54 (65.9%) were females and 28

(34.1%) were males. In 4th year BDS, 50 (59.5%) were females and 34 (40.5%) were males. Among interns, 72 (68.6%) were females, 32 (30.5%) were males, and 1 (1.0%) preferred not to say. In the other category, 111 (68.9%) were females and 49 (30.4%) were males. Among postgraduates, 43 (63.2%) were females and 25 (36.8%) were males. Thus, females predominated across all years of study.

		Year of Study					
		3 rd year BDS	4 th year BDS	Intern	Other	PGS	
Have you attended any lecture or seminar on oral myiasis	No	Count	74	61	90	139	39
		% within Year of study	90.2%	72.6%	79.0%	82.0%	77.9%
	Yes	Count	8	23	15	22	29
		% within Year of study	9.8%	27.4%	21.0%	18.0%	22.1%
Total		Count	82	84	105	161	68
		% within Year of study	100.0%	100.0%	100.0%	100.0%	100.0%

Overall, 97 (19.4%) participants had attended a lecture or seminar on oral myiasis, whereas 403 (80.6%) had not. Attendance was highest among postgraduates(27.4%), followed by others(21.0%) and interns (22.1%). Only 9.8% of 3rd year students reported attending such programs. This indicates limited academic exposure to oral myiasis across all levels.

RESULTS

Comparative knowledge ranking score of the study participants.

Year	Knowledge Percentage
Postgraduate	83.6%
3rd Year BDS	60.3%
Intern	63.4%
4th Year BDS	64.2%
Other	67.9%

On comparative evaluation of knowledge scores across academic years, postgraduates demonstrated the highest mean knowledge score (10.03 ± out of 12; 83.6%), followed by Others (8.15; 67.9%). Final year (7.70; 64.2%) and intern BDS students (7.61; 63.4%) showed comparable knowledge levels, while participants in the third year bds category demonstrated the lowest knowledge score (7.24; 60.3%). Overall, knowledge regarding oral myiasis increased with academic advancement.

Postgraduates exhibiting significantly superior understanding compared to undergraduate students.

The association between year of study and clinical exposure was statistically significant ($p = 0.002$), suggesting that clinical experience increases with academic progression.

DISCUSSION

Oral myiasis is an opportunistic parasitic infestation caused by larvae of flies belonging primarily to the

families Calliphoridae, Sarcophagidae, and Oestridae.^[13-15] Although rare, it is clinically significant due to its potential for rapid tissue destruction.

Epidemiology

Myiasis predominantly occurs in tropical and subtropical regions.^[23] Oral myiasis constitutes less than 1% of all human myiasis cases.^[24] India reports a disproportionately high number of oral cases, especially among rural populations and patients with advanced oral squamous cell carcinoma.^[28-32]

Etiology and Causative Organisms

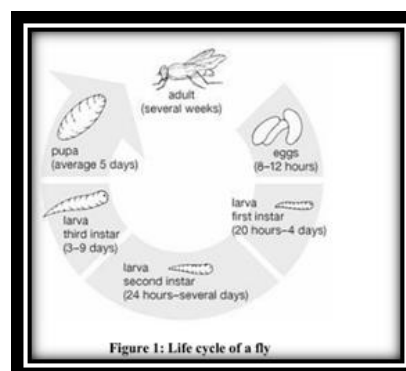
Common species implicated include:

- *Musca domestica*
- *Chrysomya bezziana*
- *Cochliomyia hominivorax*
- *Lucilia sericata*
- *Hypoderma bovis*.^[13-16]

In India, *Musca nebulo* is commonly associated with infestation.

Etiopathogenesis

The life cycle includes egg, larval (three instars), pupal, and adult stages. Eggs hatch within 8–10 hours. Larvae penetrate tissues using proteolytic enzymes and mechanical hooks, causing necrosis and foul-smelling discharge.^[17-22]



[68]

Classification**Anatomical Classification**^[9,10]

- Cutaneous
- Oral
- Nasal
- Ocular
- Internal organ myiasis

Ecological Classification^[11-13]

- Obligatory
- Facultative
- Accidental

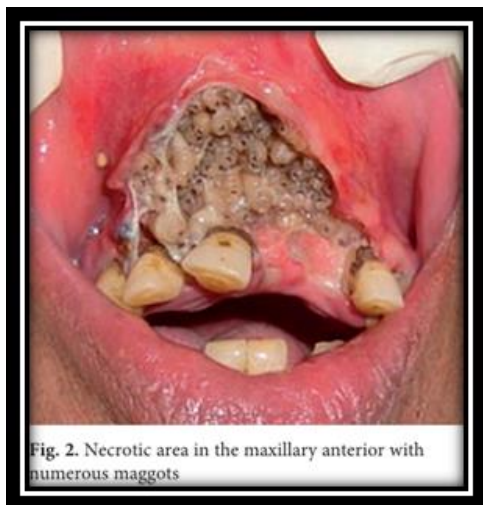
Clinical Classification^[14]

- Primary (biophagous)
- Secondary (necrobiophagous)

Oral myiasis is usually secondary, associated with necrotic tissue or malignancy.^[15]

Clinical Features

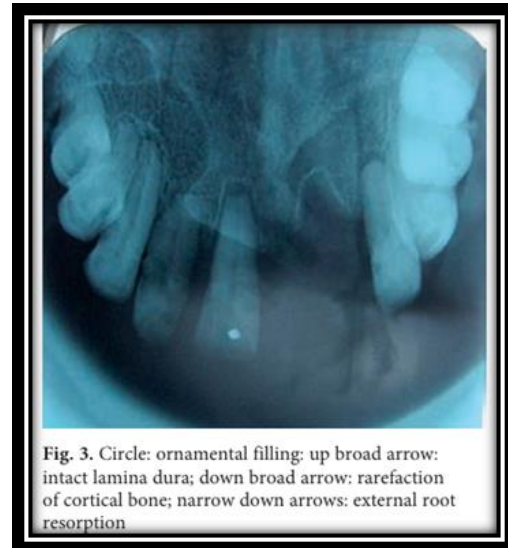
- Painful erythematous swelling
- Crawling sensation
- Maggots visible in wound
- Foul odor
- Ulceration
- Bleeding
- Loose teeth
- Osteomyelitis (in severe cases)



[69]

Radiographic Findings^[10]

- Radiolucency suggestive of bone resorption
- Mucoperiosteal thickening
- Air-fluid levels in maxillary sinus
- Soft tissue edema
- Orbital bone perforation (advanced cases)



[69]

Management

Management involves a multimodal approach:

1. Mechanical Removal

Manual extraction with forceps remains the gold standard⁴⁶

Manual extraction with blunt forceps remains the primary treatment modality.^[46]

Complete removal is essential to prevent recurrence.



[68]

2. Chemical Asphyxiation^[47-49]

Topical agents such as turpentine oil, mineral oil, ether, and iodoform are used to suffocate larvae and facilitate removal.^[47-49]

Substances such as turpentine oil, iodoform etc are applied topically by cotton pellet and keep it for 2 min.

Substance used for chemical asphyxiation are

- Turpentine oil
- Ether
- Mineral oil
- Iodoform

3. Pharmacological Therapy^[50-53]

Oral ivermectin (200 µg/kg) has demonstrated excellent systemic efficacy.^[50-52]

Ivermectin is highly effective against deep seated larvae due to its GABA agonist action paralyzing and killing parasites, Broad-spectrum antibiotics (amoxicillin-clavulanate or metronidazole) are prescribed to prevent secondary infection.^[53]

4. Supportive Care^[54-56]

- Surgical debridement
- Nutritional rehabilitation
- Management of underlying disease

5. Surgical Intervention

Debridement of necrotic tissue and management of underlying malignancy or periodontal disease.^[54]

6. Preventive Strategies

- Oral hygiene reinforcement
- Fly control measures
- Screening of debilitated patients
- Caregiver education^[65-67]

Early intervention ensures excellent prognosis; delayed treatment increases morbidity.

Early diagnosis significantly improves prognosis.

Oral myiasis, though rare (<1% of total myiasis cases)^[24], carries significant morbidity due to rapid larval invasion and tissue destruction. The higher awareness among senior students may be attributed to exposure to oral oncology cases and rural outreach postings.

India contributes disproportionately to reported cases of oral myiasis, particularly among patients with advanced OSCC.^[14,25] The strong association with malignancy emphasizes the need for oncologic vigilance among dental professionals.

The life cycle of dipterous larvae allows rapid progression from egg to invasive larval stages within 8–10 hours.^[26] Proteolytic enzymes secreted by larvae lead to tissue necrosis and secondary bacterial infection.^[27] Delayed intervention may result in orbital invasion, intracranial spread, or septicemia.^[28]

Our findings align with previous awareness studies in tropical infectious oral diseases where undergraduates showed moderate theoretical knowledge but limited clinical application.^[20-23]

Given the climatic conditions and rural demographics in India, dental students must be trained to recognize:

- Foul-smelling ulcerative lesions
- Visible maggots
- Tissue necrosis
- Risk factors such as mouth breathing and malignancy

Curriculum reform should incorporate tropical oral parasitic diseases within oral medicine training.

Awareness Implications

Studies indicate inadequate awareness among dental students.^[57-61] Considering that dental practitioners serve as frontline healthcare providers, early recognition and prompt referral are essential.

Curricular integration of tropical oral diseases and special care dentistry is recommended.^[62-64]

CONCLUSION

Oral myiasis, though rare, remains a clinically significant condition in tropical countries. This study demonstrates variable awareness among dental students, with improved knowledge among postgraduates compared to undergraduates. Strengthening academic training in opportunistic infections and parasitic oral diseases is necessary to enhance early diagnosis and management.

REFERENES

1. Hope FW. On insects and their larvae occasionally found in the human body. *Trans R Entomol Soc Lond*, 1840; 2: 256–271.
2. Zumpt F. *Myiasis in Man and Animals in the Old World*. London: Butterworths, 1965.
3. Laurence SM. A case of dipterous larvae infestation. *Br Med J.*, 1909; 2: 88.
4. Francesconi F, Lupi O. Myiasis. *Clin Microbiol Rev.*, 2012; 25: 79–105.
5. Robbins K, Khachemoune A. Cutaneous myiasis. *J Am Acad Dermatol*, 2010; 62: 907–926.
6. Singh A, Singh Z. Incidence of myiasis in India. *J Parasitol Res.*, 2015; 2015: 1–5.
7. Hall MJR, Wall R. Myiasis of humans and domestic animals. *Adv Parasitol*, 1995; 35: 257–334.
8. Sharma J et al. Primary oral myiasis. *Med Oral Patol Oral Cir Bucal*, 2008; 13: E714–E716.
9. McGraw TA, Turiansky GW. Cutaneous myiasis. *J Am Acad Dermatol*, 2008; 58: 907–926.
10. Gupta A et al. Imaging findings in rhino-orbital myiasis. *Indian J Radiol Imaging*, 2011; 21: 62–64.
11. Sherman RA. Wound myiasis. *Arch Intern Med.*, 2000; 160: 2004–2014.
12. Bishara J et al. Pseudomyiasis. *Clin Infect Dis.*, 1995; 21: 135–139.
13. Prabhu SR et al. *Oral Diseases in the Tropics*. Oxford, 1992.
14. Kumar P et al. Oral myiasis in OSCC. *J Oral Maxillofac Pathol*, 2019; 23: 456–460.
15. Rao GS et al. Oral myiasis in mentally challenged. *Indian J Dent Res.*, 2012; 23: 112–115.
16. Bhatt AP, Jayakrishnan A. Oral myiasis: A case report. *Int J Paediatr Dent*, 2000; 10(1): 67–70.
17. Shinohara EH, Martini MZ, de Oliveira Neto HG, Takahashi A. Oral myiasis treated with ivermectin: case report. *Braz Dent J.*, 2004; 15(1): 79–81.
18. Reddy MH, Das N, Vivekananda MR. Oral myiasis in a patient with advanced carcinoma of buccal mucosa. *J Oral Maxillofac Pathol*, 2012; 16(2): 289–291.

19. de Arruda JA, Silva LV, Monteiro JL, et al. Extensive oral myiasis: case report and literature review. *J Clin Exp Dent*, 2017; 9(2): e277–e280.
20. Rai S, Hegde AM, Shetty S. Awareness of oral parasitic infections among dental students. *J Indian Acad Oral Med Radiol*, 2013; 25(4): 301–305.
21. Patil K, Mahima VG, Lahari K. Oral myiasis: a review. *J Oral Maxillofac Pathol*, 2009; 13(2): 67–70.
22. Kumar GS, Sowmya SV, Shivananda S. Oral myiasis in a neurologically compromised patient. *Contemp Clin Dent*, 2013; 4(2): 244–247.
23. Ahmed MK, Bansal S, Dhillon M. Knowledge of tropical oral diseases among dental interns. *J Educ Ethics Dent.*, 2014; 4(1): 12–16.
24. Francesconi F, Lupi O. Myiasis. *Clin Microbiol Rev.*, 2012; 25(1): 79–105.
25. Kumar P, Singh V, Singh A. Oral myiasis associated with oral squamous cell carcinoma: A case report. *J Oral Maxillofac Pathol*, 2019; 23(3): 456–460.
26. Hall MJR. The biology of myiasis-causing flies. *Parasitol Today*, 1997; 13(9): 361–366.
27. Sherman RA, Wyle FA. Low-cost, low-maintenance rearing of maggots in hospitals. *Am J Trop Med Hyg*, 1996; 54(1): 38–41.
28. Pandey A, Madan M, Asthana AK. Maxillofacial myiasis: a rare entity. *J Maxillofac Oral Surg*, 2009; 8(1): 90–92.
29. Vyas SP, Raval PK, Shah RP. Oral myiasis: report of two cases. *Indian J Otolaryngol Head Neck Surg*, 2010; 62(3): 310–312.
30. Singh I, Gathwala G, Yadav SP. Myiasis in children: the Indian perspective. *Int J Pediatr Otorhinolaryngol*, 1993; 25(1-3): 127–131.
31. Bhatia SK, Mohan S, Sood S. Oral myiasis: a case report. *Indian J Dent Res.*, 2005; 16(2): 67–69.
32. Sood VP, Kakar PK, Wattal BL. Myiasis in malignant wounds. *J Laryngol Otol*, 1976; 90(9): 847–853.
33. Cramer JD, Purkey MR, Smith SS. Head and neck myiasis: review of cases. *Otolaryngol Head Neck Surg*, 2015; 153(2): 191–198.
34. Villwock JA, Harris TM. Myiasis of the head and neck. *Ear Nose Throat J.*, 2014; 93(10-11): E30–E33.
35. Talari SA, Sadr B, Doroodgar A. Oral myiasis: case report. *Iran J Parasitol*, 2004; 1(1): 45–49.
36. Yadav S, Singh A, Kumar P. Gingival myiasis: rare presentation. *J Clin Diagn Res.*, 2014; 8(8): ZD25–ZD26.
37. Passos MRL, Ferreira DC. Human myiasis in Brazil: epidemiology and clinical features. *Rev Inst Med Trop Sao Paulo*, 2012; 54(6): 345–349.
38. Singh A, Singh Z. Incidence of myiasis among humans—a review. *Parasitol Res.*, 2015; 114(9): 3183–3199.
39. Verma P, Mehrotra V. Oral myiasis: clinical review. *Natl J Maxillofac Surg*, 2013; 4(2): 230–233.
40. Karjodkar FR. *Textbook of Dental and Maxillofacial Radiology*. 2nd ed. New Delhi: Jaypee, 2011.
41. White SC, Pharoah MJ. *Oral Radiology: Principles and Interpretation*. 7th ed. St Louis: Mosby., 2014.
42. Goyal S, Jhamb A, Singh PP. CT findings in rhino-orbital myiasis. *Indian J Radiol Imaging*, 2011; 21(2): 129–131.
43. Turhan O, Mutlu H, Ozdemir M. Nasal myiasis: radiologic findings. *Eur Arch Otorhinolaryngol*, 2006; 263(4): 364–367.
44. Kumar N, Gupta R, Kumar S. Maxillary sinus myiasis: CT evaluation. *J Laryngol Otol*, 2007; 121(4): e9.
45. de Oliveira JC, de Oliveira GA. Imaging aspects of facial myiasis. *Oral Surg Oral Med Oral Pathol Oral Radiol Endod*, 2008; 105(3): e22–e26.
46. Shinohara EH, Martini MZ, Oliveira HG. Treatment of oral myiasis with manual removal. *Braz Dent J.*, 2004; 15(1): 79–81.
47. Sharma D, Shukla AK. Chemical agents in management of myiasis. *Trop Doct*, 1990; 20(4): 170–171.
48. Kakar PK, Sood VP. Turpentine oil in treatment of myiasis. *J Laryngol Otol*, 1976; 90(9): 847–853.
49. Singh G, Sharma S. Iodoform application in oral myiasis. *Indian J Dent Res.*, 2003; 14(2): 69–71.
50. Chaccour C, Hammann F, Rabinovich NR. Ivermectin and its use in parasitic diseases. *Expert Rev Anti Infect Ther.*, 2017; 15(9): 823–834.
51. Victoria J, Trujillo R, Barreto M. Ivermectin in oral myiasis. *Am J Trop Med Hyg.*, 1999; 60(4): 560–562.
52. Marty FM, Neafie RC, Wear DJ. Furuncular myiasis treated with ivermectin. *Clin Infect Dis.*, 2005; 40(9): e1–e3.
53. Brook I. Secondary bacterial infections in myiasis. *J Med Microbiol*, 2002; 51(4): 355–357.
54. Sherman RA. Maggot therapy for wound healing. *Clin Infect Dis.*, 2003; 37(10): 1377–1383.
55. Francesconi F, Lupi O. Myiasis: clinical management. *Clin Microbiol Rev.*, 2012; 25(1): 79–105.
56. Bapat U, Kedarnath N, Bhake A. Fatal oral myiasis in advanced carcinoma. *J Cancer Res Ther.*, 2010; 6(2): 221–223.
57. Rai S, Hegde AM. Awareness of oral parasitic diseases among dental students. *J Indian Soc Pedod Prev Dent.*, 2012; 30(4): 298–302.
58. Patil K, Mahima VG. Knowledge of tropical oral diseases among undergraduates. *J Educ Ethics Dent*, 2013; 3(2): 72–76.
59. Kumar A, Sinha RK. Awareness of opportunistic infections in dentistry. *J Clin Diagn Res.*, 2015; 9(5): ZC01–ZC04.
60. Gupta N, Singh R. Dental curriculum and neglected tropical diseases. *J Dent Educ.*, 2014; 78(10): 1442–1448.
61. Thomas S, Nair P. Diagnostic delays in rare oral infections. *Oral Surg Oral Med Oral Pathol Oral Radiol*, 2016; 121(5): e129–e134.

62. World Health Organization. Control of neglected tropical diseases. WHO Technical Report Series. Geneva: WHO, 2010.
63. Petersen PE. The World Oral Health Report. Community Dent Oral Epidemiol, 2003; 31(1): 3–24.
64. Frencken JE, Sharma P, Stenhouse L. Global epidemiology of oral diseases. Int Dent J., 2017; 67(3): 139–146.
65. Hall MJR, Farkas R. Traumatic myiasis prevention strategies. Vet Parasitol, 2000; 91(1-2): 151–158.
66. Otranto D, Stevens JR. Molecular approaches to myiasis epidemiology. Trends Parasitol, 2002; 18(9): 418–423.
67. McGarry JW, Donnelly M. Prevention and management of human myiasis. BMJ., 1999; 318: 1115–1116.
68. Toral D, Mehta¹, Palak A, Patel Shruti B, Ganvit, Avni D, Patel Unveiling the Threat of Oral Myiasis in Oral Carcinoma: A Retrospective Observational Study of Causes and Care.
69. Vela Desai^A, Swati Phore^B, D, Pallavi Baghla^C © Copyright by Wroclaw Medical University and Polish Dental Society Primary Oral Myiasis – Rare Case Report.