

**PLEURO-PULMONARY METASTASES FROM RECURRENT PERITONEAL  
DESMOPLASTIC SMALL ROUND CELL TUMOR (DSRCT)****\*Mouhssine N., Msika S., Arfaoui H., Sqalli Houssini Z., Bamha H., Bougteb N., EL Khattabi W., Afif My H.**

Department of Respiratory Diseases, Hôpital 20 Août, CHU IBN Rochd, Casablanca, Morocco.

**\*Corresponding Author: Mouhssine N.**

Department of Respiratory Diseases, Hôpital 20 Août, CHU IBN Rochd, Casablanca, Morocco.

DOI: <https://doi.org/10.5281/zenodo.19415823>**How to cite this Article:** \*Mouhssine N., Msika S., Arfaoui H., Sqalli Houssini Z., Bamha H., Bougteb N., EL Khattabi W., Afif My H. (2026). Pleuro-Pulmonary Metastases From Recurrent Peritoneal Desmoplastic Small Round Cell Tumor (DsRCT). World Journal of Pharmaceutical and Medical Research, 12(4), 223–226.

This work is licensed under Creative Commons Attribution 4.0 International license.



Article Received on 05/03/2026

Article Revised on 25/03/2026

Article Published on 01/04/2026

**ABSTRACT**

Desmoplastic small round cell tumors (DSRCT) belong to the group of malignant small round cell tumors that primarily affect children and young adults. This group includes Ewing sarcomas, peripheral neuroectodermal tumors (PNET), embryonal rhabdomyosarcomas, neuroblastomas, and desmoplastic small round cell tumors. DSRCT is a rare and highly aggressive malignant tumor. Its origin is most often intra-abdominal, without an obvious visceral primary site, and it is almost always associated with the presence of an abdominal mass and/or peritoneal carcinomatosis. More rarely, initial mediastinal, pleural, paratesticular, osseous, and intracranial localizations have been reported.<sup>[1]</sup> We report the case of a 22-year-old patient with pleural and pulmonary involvement of desmoplastic small round cell tumors.

**KEYWORDS:** Desmoplastic small round cell tumor, pleural metastases, pulmonary metastases.**INTRODUCTION**

Desmoplastic small round cell tumor (DSRCT) is a rare and highly aggressive malignant tumor, most frequently located in the abdomen, and more rarely in the mediastinum, pleura, or lungs. We report the case of a 22-year-old patient with a history of recurrent peritoneal desmoplastic small round cell tumor, previously treated with surgery combined with chemotherapy and radiotherapy, who presented with pulmonary and pleural metastases.

**CASE PRESENTATION**

A 22-year-old patient with no history of toxic habits had been followed for three years for a desmoplastic small round cell tumor (DSRCT) of the peritoneum. The disease initially presented with masses located at the left colic flexure, in the rectovesical pouch, at the root of the mesentery, and within the mesentery of the terminal ileal loop.

Immunohistochemical analysis of the biopsy showed tumor cells expressing CKAE1/AE3 and focally desmin (D33), with negative WT1 expression. The patient received neoadjuvant chemotherapy, followed by surgical resection of the peritoneal masses. Surgical

exploration revealed a 12-cm mass adherent to the left colic flexure and the greater omentum, in close contact with the spleen, stomach, and pancreatic tail without evidence of invasion, as well as a 7-cm mass in the rectovesical pouch. The patient subsequently received chemotherapy (vincristine, cyclophosphamide, mesna, and doxorubicin) and radiotherapy.

Seven months prior to consultation, the patient reported the reappearance of diffuse abdominal pain, without bowel habit disturbances or gastrointestinal bleeding. Abdominopelvic MRI revealed disease recurrence with an increase in the number and size of right subphrenic peritoneal nodules (Figure 1).

The patient reported a dry cough that became mucopurulent, associated with right basal thoracic pain, evolving over two months, without other thoracic or extra-thoracic symptoms. These symptoms occurred in a context of apyrexia and deterioration of general condition.

Clinical examination found a patient in relatively good general condition (performance status 1), with clinical signs of pleural effusion of the lower two-thirds of the

right hemithorax and abdominal tenderness on palpation, without evidence of an abdominal mass. The remainder of the physical examination was unremarkable.

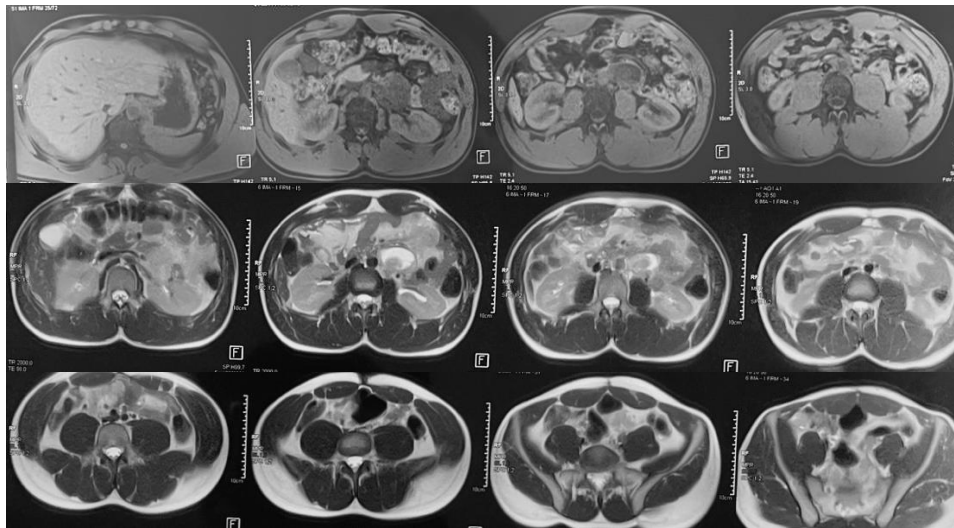
A chest X-ray showed multiple bilateral nodular opacities, a right pleural opacity, and interlobar fissure involvement (Figure 2). Chest computed tomography (CT) demonstrated multiple bilateral pulmonary nodules, bilateral pleural effusion with nodular pleural thickening, and a small pericardial effusion (Figure 3).

Diagnostic thoracentesis revealed a serofibrinous pleural effusion (protein level: 54.6 g/L, positive Rivalta test, lymphocytes 70%). Pleural biopsy showed fibrous tissue infiltrated by a tumor proliferation composed of nests, clusters, and cords of cells with moderately eosinophilic cytoplasm and hyperchromatic nuclei with moderate cytonuclear atypia and a moderate mitotic index.

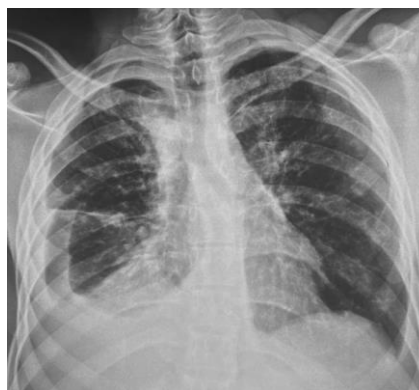Immunohistochemical analysis demonstrated positivity for polyclonal cytokeratin, desmin, and cytokeratin 7, and negativity for myogenin, smooth muscle actin, and TTF-1, consistent with pleural metastasis of desmoplastic small round cell tumor.

Flexible bronchoscopy revealed tumor-like infiltration of the middle lobe bronchus, and bronchial biopsies confirmed secondary involvement by DSRCT.

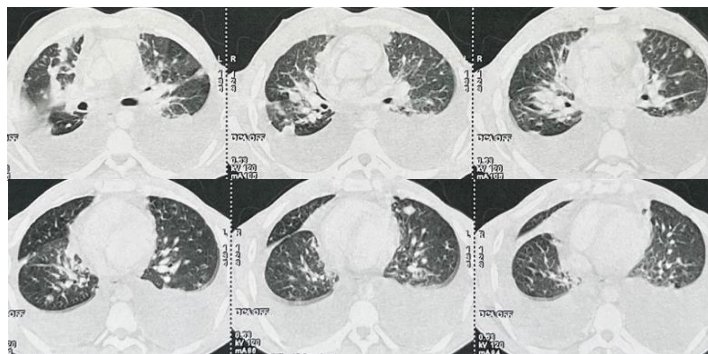
The diagnosis of pleuro-pulmonary metastases from recurrent peritoneal desmoplastic small round cell tumor was established. Following multidisciplinary team discussion, the patient was referred for palliative chemotherapy and pleural talc pleurodesis.



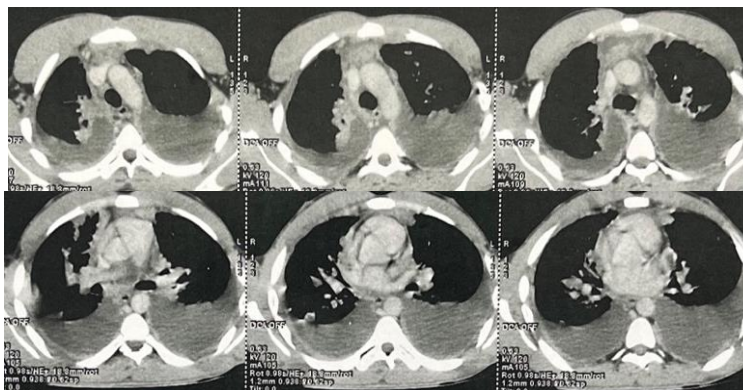
**Figure 1:** Abdominopelvic MRI showing peritoneal soft-tissue masses, predominantly in the subsplenic region and left flank, the largest measuring at the level of D12–L1, associated with peri-hepatic peritoneal thickening, consistent with disease recurrence.



**Figure 2:** Chest X-ray: Shows bilateral nodular opacities, a right-sided pleural-type opacity, and interlobar fissure involvement.



**Figure 3: Chest CT (lung window): Demonstrates bilateral pulmonary nodules.**



**Figure 4: Chest CT (mediastinal window): Shows bilateral pleural effusion.**

## DISCUSSION

Desmoplastic small round cell tumor (DSRCT) is a malignant tumor that typically affects children and young adult males.<sup>[2]</sup> These tumors can be difficult to diagnose because of their rarity and their non-specific demographic, clinical, and radiological characteristics.<sup>[3]</sup> DSRCT most commonly arises in the peritoneum, but it may also involve the ovaries, liver, kidneys, pancreas, bones, skull, and the head and neck region. However, a few cases of pulmonary and pleural DSRCT have also been reported.<sup>[4-5]</sup>

Clinical manifestations depend largely on the site of the tumor. In cases of abdominal involvement, patients may present with abdominal distension, abdominal pain, an abdominal mass, ascites, hepatomegaly, bowel habit disturbances, or intestinal obstruction.<sup>[6-7]</sup>

Clinical signs associated with thoracic involvement are also non-specific. In cases of pleural localization, the tumor may progress rapidly and can metastasize to the abdominal and pelvic cavities at an advanced stage, which is associated with a poor prognosis.<sup>[8,9]</sup>

Contrast-enhanced computed tomography (CT) and magnetic resonance imaging (MRI) demonstrate the presence of a soft-tissue mass, which may mimic malignant mesothelioma in cases of pleural localization. Fluorodeoxyglucose positron emission tomography/computed tomography (FDG PET/CT) may provide additional information for disease staging.<sup>[10,11]</sup>

From a histological perspective, DSRCT is difficult to distinguish from other malignant small round cell tumors. The main histological features of DSRCT include a well-defined distribution of small round cells arranged in nests, islands, or cords, surrounded by abundant fibrous stromal tissue.<sup>[9]</sup> Hemorrhagic and necrotic areas may be observed within the tumor, and stromal tumor vessels with marked hypertrophy can be present in hemorrhagic regions.

Immunohistochemical findings generally indicate multidirectional differentiation of tumor cells. Markers typically showing positivity include epithelial cytokeratin, epithelial membrane antigen (EMA), the mesenchymal marker vimentin, the myogenic marker desmin, neural cell adhesion molecule (NCAM), and neuron-specific enolase (NSE).

In the present case, immunohistochemical analysis showed positivity for desmin, polyclonal cytokeratin (PCK), vimentin, CD99, and EMA, which is overall consistent with the pathological characteristics of DSRCT. Multilineage differentiation is considered one of the key features of DSRCT.

The review by Alessandro Giuseppe Fois aimed to discuss the demographic, pathological, clinical, and therapeutic characteristics of pleural desmoplastic small round cell tumor based on 14 articles published between 1989 and 2017. The mean age of patients was 25.5 years, with a male predominance. Chest pain, pleural effusion,

and dyspnea were the most common clinical manifestations.

A surgical biopsy was performed in 80% of cases to establish the diagnosis, whereas pleural needle biopsy was diagnostic in only two patients. A multidisciplinary approach combining surgery, chemotherapy, and radiotherapy was adopted in most cases. Only two patients were still alive three years after diagnosis, reflecting the aggressive nature of the disease and the poor outcomes associated with currently available treatments.<sup>[3]</sup> In general, a surgical or thoracoscopic biopsy is required to establish a definitive diagnosis. Video-assisted thoracoscopic surgery (VATS) is a minimally invasive technique with high diagnostic potential in cases associated with pleural effusion and pleural thickening, as it allows direct visualization of lesions and the performance of multiple pleural biopsies.<sup>[12–13]</sup>

Pulmonary localization has been described in one case reported in the literature, involving a 21-year-old female patient who presented with a left mediastino-pulmonary mass associated with a large serohemorrhagic pleural effusion. Bronchial biopsies of the tumor partially obstructing the left main bronchus, as well as biopsy of the subcarinal lymph node obtained by endobronchial ultrasound (EBUS) and pleural biopsy, were insufficient to confirm the nature of the tumor.

The final diagnosis was established only at autopsy, as the patient died following a surgical lung biopsy.<sup>[14]</sup> The optimal treatment for DSRCT remains non-consensual, and the question of the best therapeutic strategy remains open. In cases of abdominal localization, the combination of multi-agent chemotherapy and the most complete surgical resection possible, associated with whole-abdominal radiotherapy, is currently the preferred treatment approach in most centers. The overall survival rate is approximately 20%, and outcomes appear slightly more favorable in patients who undergo complete surgical resection. When multiple pulmonary metastases are identified, the literature recommends combined chemotherapy including doxorubicin, etoposide, vincristine, cisplatin, and either ifosfamide or cyclophosphamide.<sup>[15,16]</sup>

## CONCLUSION

Desmoplastic small round cell tumor (DSRCT) is a rare and aggressive malignant tumor with a poor prognosis, most commonly arising in the abdomen. Pleural or pulmonary metastases may be present at initial diagnosis or during disease progression. An aggressive multimodal therapeutic approach, combining several treatment modalities, may provide temporary survival benefits for patients affected by this disease.

Conflict of Interest: The authors declare no conflict of interest.

## REFERENCES

1. Maliki M, Mahassini N, Zouaidia F, Bernoussi Z, Mansouri F, El Hachimi A. Tumeur desmoplastique intraabdominale à petites cellules rondes. A case report. *Rev Med Liège*, 2004; 59: 451–454.
2. Volkan. A et al: Primary D.
3. Chouli M, Viala J, Dromain C, Fizazi K, Duvillard P, Vanel D: Intra-abdominal desmoplastic small round cell tumors: CT findings and clinicopathological correlations in 13 cases. *Eur J Radiol*, 2005; 5: 438–442.
4. Fois et al. *Multidisciplinary Respiratory Medicine*, 2017; 12: 22.
5. Ikeue T, Ohi I, Noguchi S, et al. Desmoplastic small round cell tumor of the pleura successfully treated with a lower dose of pazopanib. *Intern Med*, 2016; 55: 2463–7.
6. Ikeue T, Ohi I, Noguchi S, et al. Desmoplastic small round cell tumor of the pleura successfully treated with a lower dose of pazopanib. *Intern Med*, 2016; 55: 2463.
7. de Araujo RA, Araujo BJ. Desmoplastic small round cell tumor: report of 2 cases treated with chemotherapy alone or in combination with bevacizumab. *Case Rep Oncol*, 2014; 7: 102–8.
8. Xu J, Yao M, Yang X, et al. Desmoplastic small round cell tumor of the middle ear: a case report. *Medicine*, 2018; 97: e0494.
9. Tarek N, Hayes-Jordan A, Salvador L, et al. Recurrent desmoplastic small round cell tumor responding to an mTOR inhibitor containing regimen. *Pediatr Blood Cancer*, 2017; 65: e26768.
10. Shi C, Feng Y, Zhang LC, et al. Effective treatment of apatinib in desmoplastic small round cell tumor: a case report and literature review. *BMC Cancer*, 2018; 18: 338.
11. W.D. Zhang, C.X. Li, Q.Y. Liu, Y.Y. Hu, Y. Cao, J.H. Huang, et al., FDG-PET/CT imaging findings of abdominopelvic desmoplastic small round cell tumors: correlation with histopathological findings, *Eur. J. Radiol*, 2010; 20: 2257e2264.
12. Z.M. Wang, W.B. Xiao, S.S. Zheng, Desmoplastic small round cell tumor of the lung: case report, *Chin. Med. J. Engl*, 2007; 120: 2327e2328.
13. G. Ostoros et al. / *Lung Cancer*, 2002; 36: 333/336.
14. Attene F, Paliogiannis P, Scognamillo F, Marrosu A, Trignano M. Single access Videothoracoscopic biopsy and talc Pleurodesis in patients with malignant pleural effusion. *Hell J Surg*, 2012; 84: 304–7.
15. M.A. Ariza-Prota et al. / *Respiratory Medicine Case Reports*, 2015; 16: 112e116.
16. Ikeue T, Ohi I, Noguchi S, Fukao A, Terashita S, Horikawa S, et al. Desmoplastic small round cell tumor of the pleura successfully treated with a lower dose of Pazopanib. *Intern Med.*, 2016; 55: 2463–7.
17. Imamura F, Funakoshi T, Nakamura S, et al. Primary primitive neuroectodermal tumour of the lung: report of two cases. *Lung Cancer*, 2000; 27: 55/60.