

EVIDENCE-BASED HOMEOPATHIC INTERVENTION IN HERPETIC GEOMETRIC GLOSSITIS: A CASE REPORT OF HOLISTIC HEALING**¹*Dr. Kanchan Sanjay More and ²Dr. Nilesh Rajendra Deore**¹Assistant Professor, Department of Surgery, Smt. K.B. Abad Homeopathic Medical College, Chandwad, Nashik.²Assistant Professor, Department of Practice of Medicine, Smt. K.B. Abad Homeopathic Medical College, Chandwad, Nashik.***Corresponding Author: Dr. Kanchan Sanjay More**

Assistant Professor, Department of Surgery, Smt. K.B. Abad Homeopathic Medical College, Chandwad, Nashik.

Article Received on 07/07/2025

Article Revised on 28/07/2025

Article Accepted on 18/08/2025

ABSTRACT

India is called as 'Oral cancer capital' but along with oral carcinoma other oral diseases are also considered as a major problem nowadays. Glossitis is one of the commonest diseases encountered on daily basis in clinical practice. It is due to lack of hygiene, lack of knowledge, low dental health policy, low immunity & huge consumption of tobacco. Herpetic geometric glossitis refers to a chronic lesion associated with Herpes simplex virus type I infection, in which there is a deep fissure in the midline of the tongue. The lesion is usually very painful, and there may be erosions present in the depths of the fissures. Homeopathy is playing a good intervention role for dental diseases. Homeopathic remedies not only work symptomatically but it's also taking care of psychological aspect of the patient. This overview cover-up the basic principles of Homeopathy, Holistic approach to the patient & reduces chances of recurrence. In this article we are discussing the case of 39-year-old female who is suffering with herpetic geometric glossitis and she is treated and healed with homeopathic medicines.

KEYWORDS: Herpetic, Glossitis, fissured tongue, Oro-dental care, herpes HSV1, Simillimum, homeopathy.**ABBREVIATIONS**

HSV- Herpes simplex virus, HTN –Hypertension, DNA –deoxyribonucleic acid, SES- socio- economic status, IPR- Inter-personal relationship, BP – Blood pressure, Agg – aggravations, min –minute, mm/hg –millimeter of mercury, Kg – kilogram, Rx – A medical prescription.

INTRODUCTION

Tongue is one of most sensitive organ of our body and it is the beginning and only visible part of our gastrointestinal tract. The oral mucosa is the target of a number of infectious processes caused by a range of organism which are considered under various viruses, bacteria & fungi. The main viruses causing oral mucosal infections are the large herpes of virus but it can also be caused by coxsackieviruses, human papillomaviruses and others. These viruses are a group of DNA viruses which cause a range of oral & systemic diseases. There are two types of herpes simplex type1 (HSV-1) & herpes simplex type 2 (HSV2). classically, HSV-1causes oral disease, whereas HSV -2 causes genital disease.^[1]

Clinically HSV-1 infection is presented as severe form of acute herpetic glossitis.(discomfort & pain in the

tongue). The virus causes a viremia, fever, malaise & lymphadenopathy. Patient experiences discomfort in eating and drinking & eventually dehydration.^[1]

Geographic tongue is also a sequel of HSV in later stages. it is also known as migratory glossitis or erythema migrans. It usually affects the whole tongue, although less commonly it may affect the oral mucosal sites. It is characterized by erythematous patches surrounded by a margin of white pinhead lesions. Geographic tongue may be quite severe & in these circumstances tends to cause lobulation and fissuring of the tongue.^[2]

Progress of the disease – HSV is a neurogenic virus and on recovery from the primary infection the virus may become latent within the trigeminal ganglia or basal ganglia of the brain and may subsequently, be reactivated to cause a secondary infection.^[2]

The diagnosis is usually made on clinical grounds and confirmations are academic since the infection is self - limiting except in immune defects. The diagnosis can be confirmed by direct immunofluorescence of vesicular

fluid to detect the virus using specific antiserum, by inoculation of cell culture antibody titer during the acute phase of disease.^[1]

The treatment of primary herpetic glossitis comprises supportive therapy in the form of oral fluids, analgesia such as paracetamol which is also antipyretic & an antiseptic mouth wash such as chlorhexidine, sodium perborate or hydrogen peroxide.^[3]

Homoeopathic treatment for glossitis helps to reduce inflammation & swelling of the tongue & also help in reducing the recurrence. In homoeopathy, we do not treat the diseases, but the diseased individuals are treated by

Chief Complaints

Location	Sensation	Modality	Concomitant
Tongue (whole)	Burning +++ Pricking pain ++	<eating +++ <drinking +++	-

Past history: history of herpes 6 month ago. Took Ayurvedic Treatment for it.

Family history: Father - HTN
Mother - HTN

Patient as a person

Appetite – reduced due to pain.

Cravings – oily food +, Pickle++, Spicy food ++, salty things ++

Aversion – Spinach ++

Thermal – Hot

Perspiration – Profuse on exertion in axilla and back.

Digestion – Satisfactory, soft stool, everyday evacuation.

Micturition – 4-5 times/day, non-offensive, transparent

Sun aggravation – headache after exposure to sun heat.

Fasting – intolerable suffer with hyperacidity & headache.

LIFE SPACE INVESTIGATION

A 39 –year- old lady belongs to a middle class family she was married at an early age, though she wanted to pursue her career & do something in life. She had to face many issues after marriage as her husband was alcoholic and IPR with her mother in law was strained. She used to feel frustrated & dominated. She was made to undergo abortions 7-8 times due to financial stress against her will. She used to feel sad but could not react. But she never forgot that pain & suffering, she still broods keeps thinking about that. Later her husband started abusing physically then she took a stand for herself and her children as she was tired suffering and wanted freedom and respect. She decided to start a home business of sarees so that she can be financial independent. She owns her own shop now & doing well. still the bitter past haunts her & she cannot forget those events. now she wants divorce from her husband. She has dreams of unfortunate events, death of her father to whom she was very much attached & she misses him very often. She

holistic approach. The internal morbid process is expressed by means of abnormal sensations & functions followed by the appearance of the structural changes.^[7]

CASE PROFILE

Preliminary Data

Name – Mrs. A. A

Age -39 years

Sex- female

Education – 10th

Occupation – Entrepreneur

Marital status –Married

Children – Single girl child

SES – Middle class

used to feel as if she has lost her dignity during all this years of suffering but now she feels very empowered & confident.

General Examination

Appearance - lean, thin, dark complexion lady

Weight- 53kg

Pulse – 88/min

BP- 120/70 mmHg

Pallor – present+

Tongue- cracked on edges and center, slightly swollen

No oedema, no lymphadenopathy etc.

Local Examination

Tongue – slightly swollen, cracks on edges and centre. No discoloration.

Buccal cavity – yellow stained teeth, small hard rounded lump on left side of cheek. Non tender.

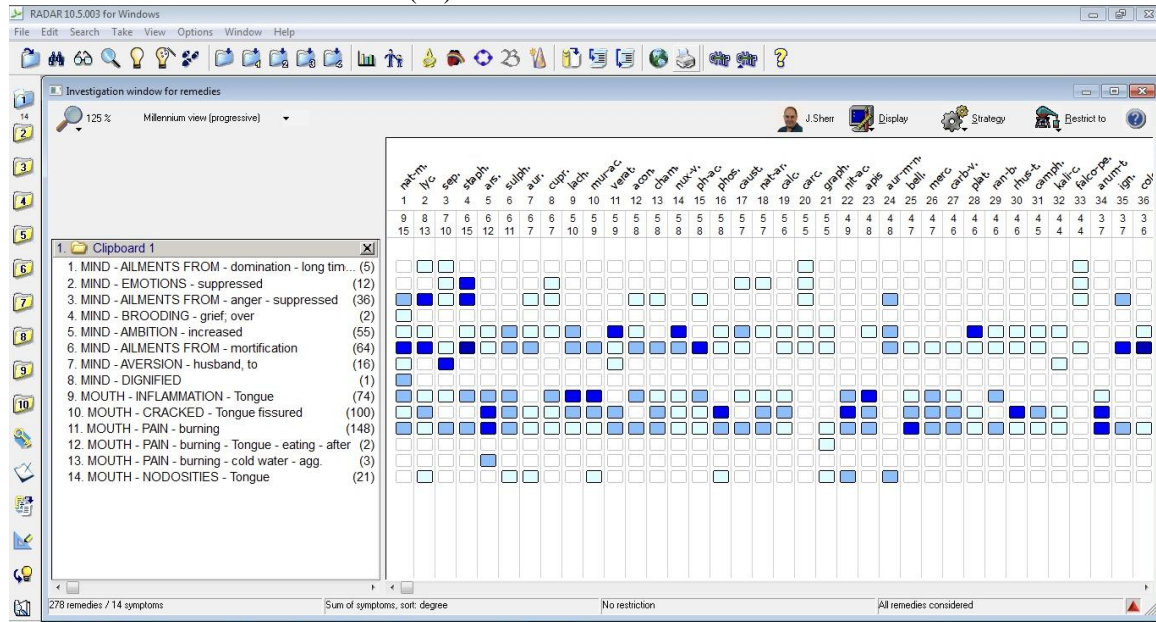
Final Diagnosis: Herpetic geometric Glossitis.^[1]

Totality of Symptoms

1. Domination by husband and mother in law
2. Suppression of emotions and anger
3. Feels she haven't received the respect she deserves
4. Brooding over past events
5. Indifference towards husband and his family
6. Hardworking & ambitious
7. Burning & pricking pain in tongue
8. Agg - eating
9. Agg – drinking
10. Small hard lump on left side of buccal cavity
11. Cracked, inflamed tongue
12. Hot patient
13. Desire pickle, salty food & spicy food
14. Aversion spinach
15. Sun heat intolerable

Repertorial totality – Repertorial approach taken: synthesis

Software used: Radar (10)

**Remedy differentiation & final selection**

Staphysagria and Natrum Muraticum covers similar grading & marks but on basis of physical generals and mental generals *Natrum mur* was given.^{[4] [5] [6] [7]}

Prescription

Date -25/01/2022

NAT MUR 200 single dose (8 globules)

Rubrum – 4 globules X 8 days

FOLLOW UP

Date	Complaint	Prescription
02/02/2022	Pain reduced, crack reduced. Mentally feeling fresh.	Rubrum 4 globules X 8 days twice a day
12/02/2022	Pain completely relieved, and the crack healed. And hard lump shrank in size as well as the consistency became soft & smooth Appetite improved, Mood better.	Rubrum 4 globules X 8 days twice a day

FOLLOW UP SUMMARY

The patient was prescribed Nat. Mur 200 single dose for 15 days. The considerable improvement on both the mental as well as the physical level were observed. her pain and other complaint has settled with the constitutional remedy.

DISCUSSION

Herpetic geometric glossitis, a chronic manifestation of Herpes Simplex Virus Type 1 (HSV-1) infection, poses significant challenges in clinical practice due to its painful and debilitating symptoms, including deep fissures on the tongue. The patient in this case report, a 39-year-old woman, presented with typical signs of HSV-induced glossitis, including intense burning and pricking pain in the tongue, which was aggravated by eating and drinking. Her history of recurrent herpes and emotional distress tied to her marital issues provided critical insights into her overall health condition. This highlights the importance of considering both physical and emotional factors in homeopathic treatment.

Homeopathy operates on the principle of treating the individual as a whole, rather than just the disease. In this

case, a constitutional remedy approach was adopted, with *Natrum muriaticum* being selected based on the patient's mental and physical symptoms. The repertorial totality, which included feelings of emotional suppression, a need for respect, brooding over past events, and physical symptoms like burning pain in the tongue, aligned well with *Natrum muriaticum*, a remedy known for addressing grief, suppressed emotions, and physical symptoms like dryness and inflammation.

The positive results observed after treatment—significant reduction in pain, healing of tongue fissures, and improvement in the patient's mood—suggest that homeopathic remedies can effectively address both the physical and emotional aspects of herpetic geometric glossitis. The improvement of the patient's emotional state, alongside the resolution of her physical symptoms, underscores the holistic approach of homeopathy, which considers the mind-body connection crucial in healing.

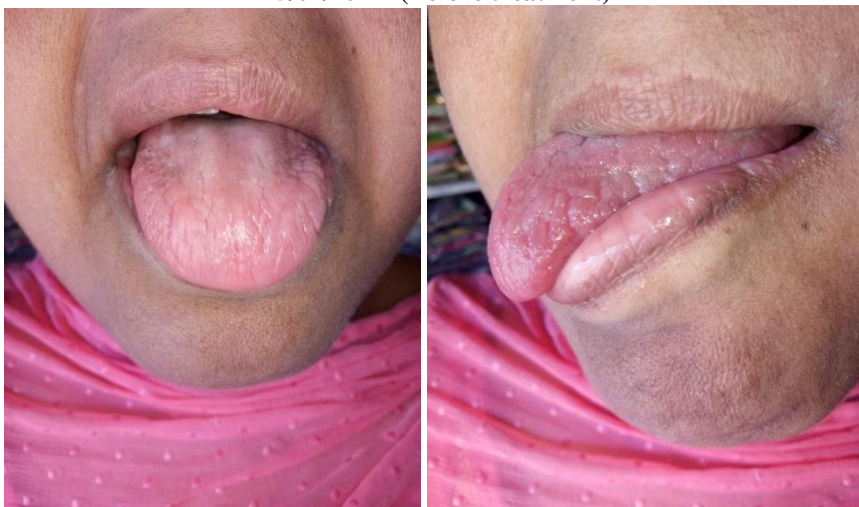CONCLUSION

This case underscores the efficacy of homeopathy in the treatment of herpetic geometric glossitis, particularly when a constitutional remedy is selected based on a

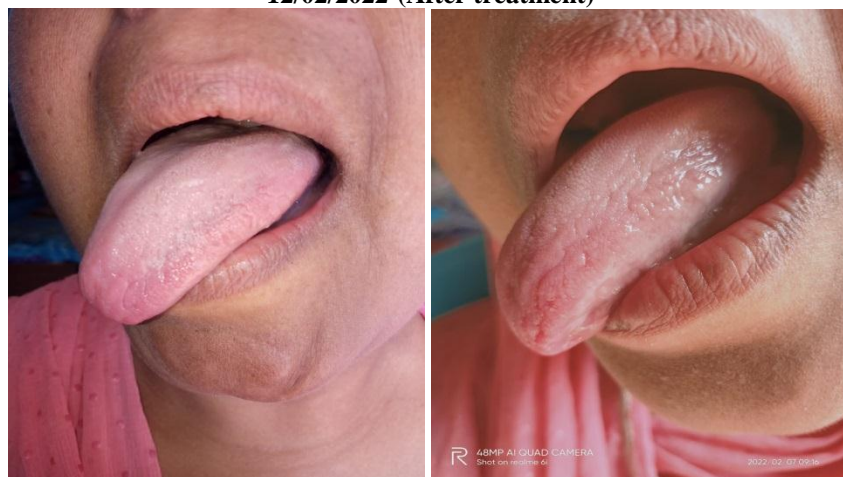
comprehensive evaluation of both physical and mental symptoms. *Natrum muriaticum*, through its action on emotional suppression and physical inflammatory processes, proved to be highly effective in this case. The patient showed significant improvement in both her tongue condition and overall emotional well-being,

suggesting that homeopathy not only addresses the symptoms but also the underlying emotional and psychological factors contributing to the disease. Further research and clinical studies are needed to validate these findings and to explore the broader potential of homeopathy in treating similar conditions.

25/01/2022- (Before treatment)



12/02/2022-(After treatment)



REFERENCES

1. Wray David, textbook of general and oral medicines, 3rd edition. Churchill Living Stone publication, 2003; 259: 260,261.
2. Scully CBE Crispian, oral & maxillofacial medicine, 3rd edition. Elsevier publication, 2004; 321.
3. Dhingra P L, Disease of ear, nose & throat, 5th edition. Elsevier publication, 2010; 233.
4. Boericke William, pocket manual of homoeopathic materia medica & repertory, reprint edition 2023. Aitbs publishers India, 2023; 459,607,409.
5. Allen H.C, Allen's keynotes, 10th edition. B.Jain Publishers, 2003; 212,290.
6. Vithoulkas George, Essence of Materia Medica, 2nd Edition. B.Jain Publishers, 1990; 188,130.
7. Aserkar A, Organon & homoeopathic philosophy for everyone, 2nd edition. pune vidyarthi griha

Prakashan, 2018; 185,178.